

Using a Clinical Protocol for Orthognathic Surgery and Assessing a 3-Dimensional Virtual Approach: Current Therapy

Luis A. Quevedo, DDS,* Jessica V. Ruiz, DDS,†
and Cristobal A. Quevedo, DDS‡

Oral and maxillofacial surgeons who perform orthognathic surgery face major changes in their practices, and these challenges will increase in the near future, because the extraordinary advances in technology applied to our profession are not only amazing but are becoming the standard of care as they promote improved outcomes for our patients. Orthognathic surgery is one of the favorite areas of practicing within the scope of practice of an oral and maxillofacial surgeon. Our own practice in orthognathic surgery has completed over 1,000 surgeries of this type. Success is directly related to the consistency and capability of the surgical-orthodontic team to achieve predictable, stable results, and our hypothesis is that a successful result is directly related to the way we take our records and perform diagnosis and treatment planning following basic general principles. Now that we have the opportunity to plan and treat 3-dimensional (3D) problems with 3D technology, we should enter into this new era with appropriate standards to ensure better results, instead of simply enjoying these new tools, which will clearly show not only us but everyone what we do when we perform orthognathic surgery. Appropriate principles need to be taken into account when implementing this new technology. In other words, new technology is welcome, but we do not have to reinvent the wheel. The purpose of this article is to review the current protocol that we use for orthognathic surgery and compare it with published protocols that incorporate new 3D and virtual technology. This report also describes our approach to this new technology.

© 2011 American Association of Oral and Maxillofacial Surgeons
J Oral Maxillofac Surg 69:623-637, 2011

In the scientific literature, we have found many articles that describe the latest developments and applications of computed tomography imaging in general,¹⁻⁵ as well as the multiple applications and advantages of cone beam computed tomography (CBCT) in particular.⁶⁻¹⁵ This imaging technology facilitates many other related applications, such as the generation of 3-dimensional (3D) models, growth and craniofacial morphology studies, virtual orthodontic planning, and virtual surgical planning, among others (Fig 1).¹⁶⁻³⁴ We strongly recommend

the article by De Vos et al,³⁵ which systematically reviews CBCT in the oral and maxillofacial region, and part I of the special series of articles that appeared in the October 2009 issue of the Journal, including the editorial by Assael.³⁶⁻³⁹ With these articles in mind and being proactive users of most of this technology in our orthognathic practice, we have found that, in many instances, new technology can prevent people from having the right attitude regarding trying to use or obtain the “new thing” without proving of its effectiveness or validation. The most important goal must be to always achieve the highest possible standards in patient care through validated treatment protocols.

Our hypothesis is that is directly related to the way we take our records and perform diagnosis and treatment planning following general basic principles.

A strict protocol to take presurgical records in our patients will give us consistent and predictable results, especially when a virtual approach will be used. These records are based on oriented natural head position (ONHP), the use of a true horizontal line as the only reference throughout the entire diagnostic and planning process, the achievement of a temporomandibular joint

*Full Professor, Oral and Maxillofacial Surgery, University of Chile, Director of Surgical-Orthodontics Institute (ICOR), Santiago, Chile.

†Orthodontist, Private Practice, and partner of Surgical-Orthodontics Institute (ICOR), Santiago, Chile.

‡Intern, Boston University Oral and Maxillofacial Surgery Department, Boston, MA.

Address correspondence and reprint requests to Dr Quevedo: ICOR Associated, Av Kennedy 5735, Torre Poniente Oficina 407 Las Condes, Santiago, Region Metropolitana, Chile; e-mail: drlquevedo@gmail.com

© 2011 American Association of Oral and Maxillofacial Surgeons
0278-2391/11/6903-0006\$36.00/0
doi:10.1016/j.joms.2010.11.009

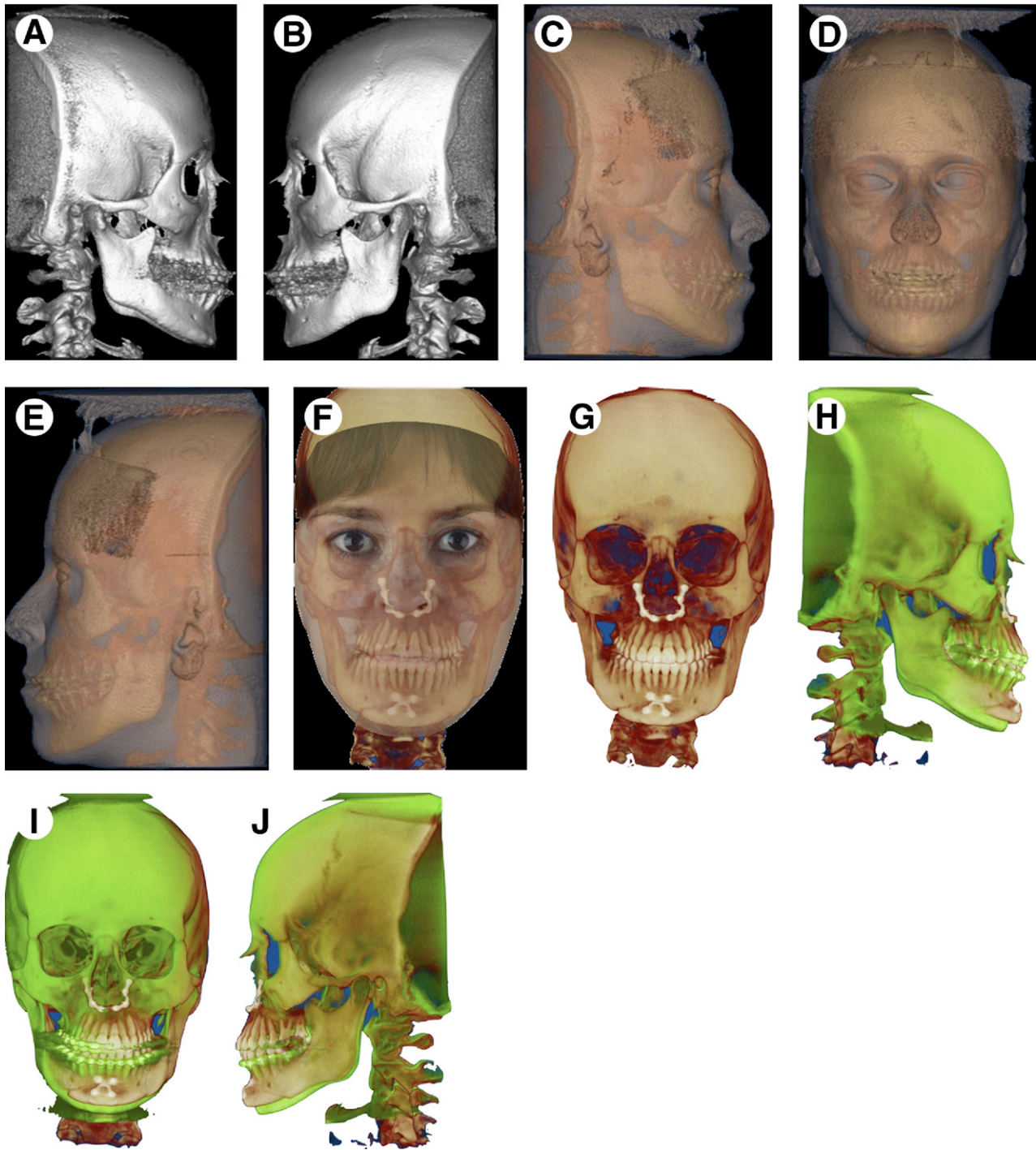


FIGURE 1. Current imaging study of an orthognathic case, using CBCT and 3D software technology. A, B, Preoperative 3D reconstruction. C, D, E, Preoperative soft/hard tissue composite. F, Postoperative soft/hard tissue composite. G, Postoperative 3D reconstruction. H, I, J, Preoperative and postoperative superimposed 3D reconstructive imaging.

Quevedo, Ruiz, and Quevedo. Clinical Protocol for Orthognathic Surgery. J Oral Maxillofac Surg 2011.

(TMJ)-centric relation, and the record of the true hinge axis when the maxilla needs to be repositioned.

Materials and Methods

It is a common practice in orthognathic surgery to develop a clinical protocol to study and plan patient

cases, and, usually, every surgical-orthodontic team applies its own modifications to the published protocols.⁴⁰⁻⁴³ In summary, these involve 3 steps. Step 1 is to establish the diagnosis. Doing so involves clinical and imaging data gathering. In our practice we use lateral and frontal cephalometric radiographs and a full-face cone beam scanner, based on which we per-

form computerized frontal and lateral Ricketts and Bjork-Jarabak analysis, along with other isolated cephalometric measurements.^{44,45} Another important diagnostic tool for us is the use of semiadjustable articulator-mounted models, for which the proper use of a face bow is very critical. Step 2 is treatment planning, which includes cephalometric prediction tracings (both computerized and manual) and model surgery. Step 3 is transferring the final plan to the operating field, which we do through the final model surgery and the fabrication of the intermediate and final surgical splints (surgical guides). This regular clinical protocol incorporates several critical steps, which are as follows.

STEP 1: DIAGNOSIS OF DENTOFACIAL DEFORMITY

A comprehensive diagnosis of a dentofacial deformity is the result of 2 main assessments. The first assessment is a static routine evaluation of several diagnostic tools by use of routine techniques. In our protocol, these so-called static studies include facial and occlusal clinical photos, radiographs, and other imaging studies; cephalometrics; and dental model studies. The second assessment is a dynamic evaluation of the patient, which includes an assessment of the capacity of the mandible to move in all directions, as well as an assessment of the TMJs, which move synchronically depending on their functional and structural health and depending on the organic (functional) relation of the patient's teeth. We will review both methods.

Static Diagnosis of Dentofacial Deformity

It is critically important that all of these studies be consistent in terms of methods to be reliable. Unfortunately, inconsistency is a common error, and it has been identified as the main cause of error in treatment planning and/or the implementation of the desired plan to the operating room.⁴⁶⁻⁵⁸ We agree with the cited literature, and we strive for consistency in our patient records. Standardization and reproducibility of the applied methods are key to achieving consistency, and to fulfill these 2 goals, we found sufficient evidence for use of the natural head position (NHP)⁵⁹⁻⁶⁷ and what has been called assisted natural head position, or ONHP,^{68,69} as positions to record our clinical photos. To identify the extension of the orientation of the assistance of the patient's own NHP, especially when we have a difficult case (a severely asymmetric face or a patient reluctant to repeat a given position), we use a spirit-level guide placed on the face bow^{44,45} (Fig 2A,B). This positioning allows us to assess our patients with respect to a true horizontal/vertical reference, which is a permanent common requirement for all of our records. For the imaging records, this assessment is achieved by use of a true vertical reference, which appears on the

lateral and frontal head radiographs by use of a plumbed chain. The patient is placed in ONHP with no ear support, with soft tissues at rest, and in first tooth contact. Since 2007, we started routinely working with a cone beam scanner (CBCT) i-CAT apparatus (Imaging Sciences International, Hatfield, PA). We quickly found that our usual, standardized way of generating images with a horizontal/vertical reference was no longer possible because, among other reasons, this new technology needed a very still patient in non-NHP.^{35,38} This limitation is still true for the majority of CBCT equipment, although the latest generations are working to improve this problem. Therefore we decided to extrapolate our method of transferring a true horizontal line to the panoramic radiograph^{44,70} to our protocol for orthognathic cases. We have been able to obtain a reliable true horizontal reference in our imaging studies by placing fiducial markers on the patient's skin to represent the true horizontal line, recorded with the assistance of a horizontal line transferring appliance (HOLTA) method.^{44,45} The accuracy of this method with a CBCT i-CAT machine was tested in an undergraduate thesis, currently in the process of being published.⁷¹ This method consists of using a face bow to establish the true horizontal reference on the patient's skin with a set of 3 HOLTA devices, through which we make a mark on each side of the patient's head, close to the tragus, and on the patient's cheek (Fig 3A,B).

We appreciate the work by Xia et al³⁸ and Gateno et al^{72,73} in this regard because they give an important role to acquiring imaging data in NHP. They also describe 2 different ways to obtain their virtual composite model in a true NHP, using a 3D laser surface scanner or a digital gyroscope.³⁸ However, we found their method to be expensive and complicated compared with ours, which is reliable, easy to use, inexpensive, and consequently, much more viable (Fig 3C,D). After this portion of the assessment, we could use standard oriented imaging to perform cephalometry. Whether we use manual or computer-generated cephalometry, and whichever analysis or software is used, it is important to obtain the structural diagnosis and related characteristics using a standardized and reliable imaging protocol.

In the diagnosis of a dentofacial deformity, conventional cephalometrics with its related advantages, such as the growth and visual treatment objectives of Ricketts et al,⁷⁴ has been in practice for many years and has been validated in numerous scientific publications.⁷⁵⁻⁸² At the point when we can conduct a true 3D cephalometric study, we should expect to have a much better understanding of dentofacial deformities, especially the asymmetric or syndrome cases. In the literature the term "3D cephalometric analysis" is confusing because it has been used in many different ways.⁸³⁻⁸⁶

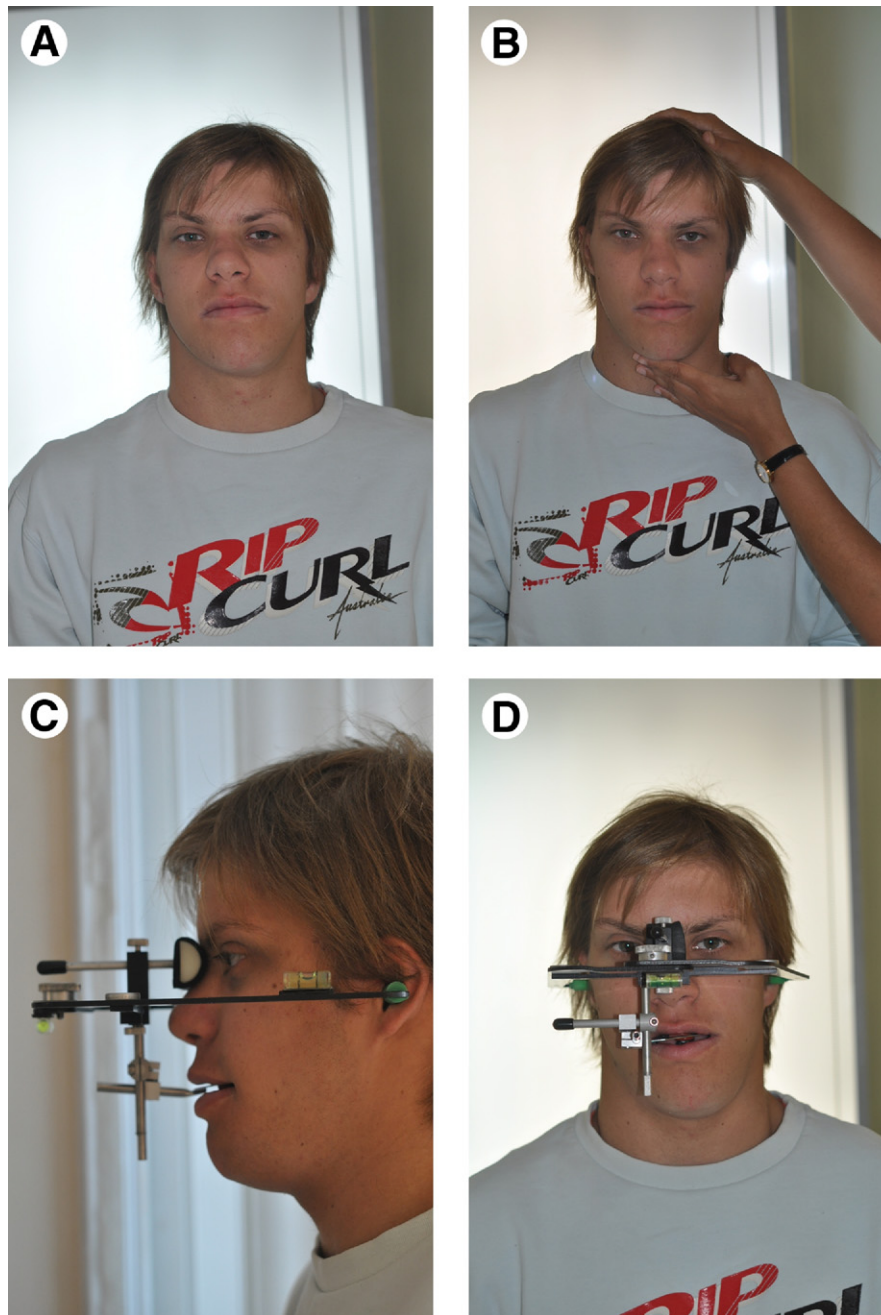


FIGURE 2. ONHP with the guide of spirit levels placed on a face bow. *A*, Asymmetric patient in his own NHP. *B*, Patient being assisted into his NHP (ONHP). *C*, The assistance is being guided with spirit leveling. *D*, Frontal view of same assistance. It should be noted that the face bow nasion support or the maxillary fork with an inferior incisor stop (or both) could be used for easy self-support of the face bow/spirit leveling approach.

Quevedo, Ruiz, and Quevedo. Clinical Protocol for Orthognathic Surgery. J Oral Maxillofac Surg 2011.

We have been exploring these new tools, and we are confident in the enormous benefits these methods will have for our patients. However, we do not think that we need to create a new cephalometric analysis to use this method. We are accustomed to using the Bjork method, modified by Jarabak, and Ricketts' frontal and lateral analyses. We aim to have the same angles and measurements in our 3D cephalogram

using the tool of projecting these angles on the corresponding plane, as suggested by Swennen et al.⁸⁵ However, in our case those planes are not anatomically related but virtually (by mathematic algorithms) constructed automatically by the software at the time of imaging orientation through the HOLTA references.

Then, we strive to have clinical photos, imaging studies, and cephalometrics taken with an equal and

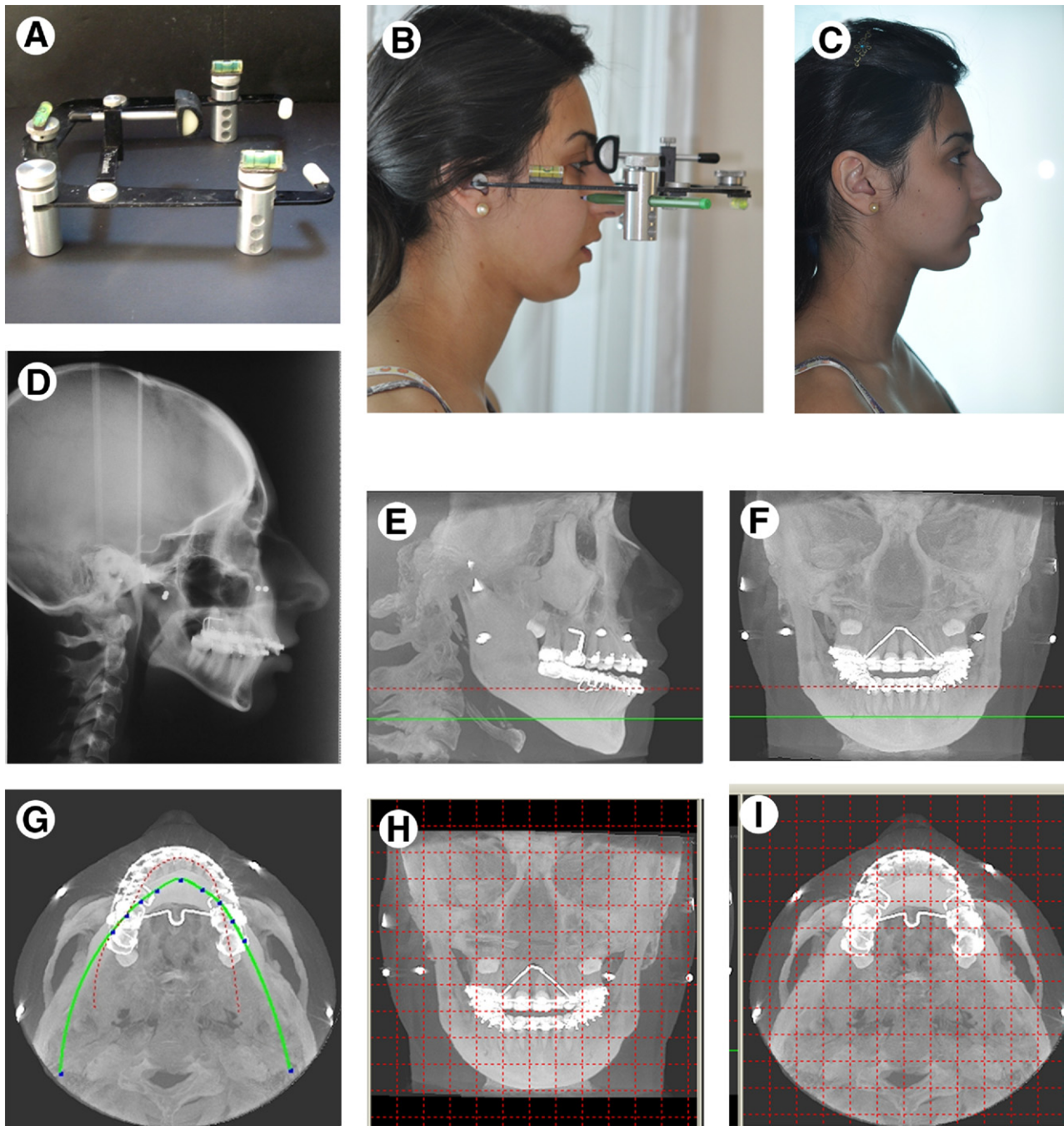


FIGURE 3. HOLTA system. A, Panoramic view of HOLTA device mounted on face bow. B, Lateral view of patient with HOLTA system in place. C, Lateral view of patient's horizontal reference painted on her skin. D, Lateral plain facial radiograph obtained with HOLTA marking. E-G, Lateral, frontal, and axial views of CBCT scan with HOLTA of same patient. H, I, Proper 3-dimensional orientation using HOLTA system. *Quevedo, Ruiz, and Quevedo. Clinical Protocol for Orthognathic Surgery. J Oral Maxillofac Surg 2011.*

consistent true horizontal reference, which allows us to study the “same patient” from both clinical and imaging records. We accomplish this by using ONHP and clinical recording of the true horizontal with the HOLTA method to consistently have it in the clinical photos and in the imaging we use.

The last of these diagnostic steps is to obtain a set of articulated dental models, which is based on the

proper use of a face bow. As established by several authors,^{54,57,58} this step is another source of multiple potential errors. We have to agree that, in a multi-step procedure, there are more opportunities to introduce mistakes, and the sum of these errors could eventually produce a poor treatment plan or a suboptimal final outcome. In performing the face bow transferring procedure to the articulator and the resulting artic-

ulated models, we recognize that these instruments are semiadjustable and limited in the replication of our patients. We should not expect these instruments to provide information other than what they are designed to provide. With proper use, this is a very useful tool, and at present, it is essential to perform the treatment planning for orthognathic surgery. We use model surgery and surgical wafers, which are fabricated in the laboratory via these articulated models,^{46,48-58} to transfer our plans to the patient in the operating theater. Most of the new approaches and the applications of new computer/virtual technology have been directed to creating a virtual wafer, which serves as a surgical splint generated by computerized treatment planning.^{4,5,16,24,29,34,36-38} We believe that this technology represents the near future, and its potential should depend more on us than the researchers or software companies developing a virtual surgical wafer. We, the clinicians using this software daily, are the real judges of the capabilities of the new achievements. From this perspective, what we ask from both of these procedures, the conventional and virtual type, is consistency, not only with respect to the procedure itself but also with respect to the rest of the records being used for diagnosis and treatment planning of the orthognathic patient. In other words, we require 1 permanent common reference for all of our records. To this end, we use a true horizontal/vertical reference. Our clinical photos, radiographs, and cephalometrics, as well as the articulated dental models for an ONHP patient, all use the same horizontal/vertical reference. Most of the semiadjustable articulators, such as Panadent, Sam's, Denar, Hanau, Whip Mix, and others,^{87,90} use what they claim to be an axio-orbitale plane, which is 2-dimensional (2D) and anatomically arbitrary, to place their face bows. Most of these articulators use a pointer to place the face bow related to the orbitale cephalometric point of the patient while the earring support is bilaterally inserted. Others, like Panadent,⁸⁹ assume that this anterior vertical reference is 22 mm from the nasion support of the face bow. When the face bow is secured on the patient's head and the transfer fork is properly locked to the patient's maxillary arch, the face bow-fork unit is brought to the articulator for the mounting procedure. Therefore these articulators use a reference that is quite different from a true horizontal one, which we use to diagnose and plan our patient cases. Whatever information we derive from this procedure will not necessarily fully correspond to our patient's dentoskeletal deformity. For this reason, we have begun using the same HOLTA method to assist our patient's NHP, and anytime the patient's deformities mandate it, we fix the transfer fork related to the position obtained in the face bow, following the frontal and lateral spirit levels^{44,45} (Fig

3A-E). With this method, we achieve consistency between clinical and imaging records as well as cephalometrics and articulated dental models because these record and models are related to 1 true horizontal/vertical reference, which is used throughout our entire diagnostic study. For example, when we decide to perform superior and anterior repositioning of the maxilla by 5 or 6 mm, we are able to accomplish this positioning correctly at surgery because the diagnosis and the treatment planning are consistent with the patient's vertical and sagittal deformity (Fig 1A,B).

Dynamic Diagnosis of Dentofacial Deformity

Dynamic in this case refers to function (ie, TMJ participation in the studied dentofacial deformity). We believe that there are 2 different aspects in which the TMJ plays a key role in the diagnosis of a dentofacial deformity. One is in the case of a structural problem that relates to the deformity (vs malformation, condylar hyperplasia, or progressive condylar resorption), and the other is in the case of a structurally healthy joint that has a condyle improperly seated in its fossa. With the availability of CBCT and its associated software, the diagnosis of TMJ structural problems is much easier, and CBCT has become the standard of care.³⁵ The condyle/fossa relation is a conceptual matter, the discussion of which is beyond the scope of this article. However, to validate our protocol we did an extensive review of the literature, which will be presented in the "Discussion" section of this article.

Our protocol for orthognathic surgery uses a full-coverage arch splint for the time the patient needs to achieve condylar seated position/centric relation (CSP/CR), to reveal the real malocclusion and its related skeletal deformity (usually between 2 and 3 months). Records are taken to obtain the real skeletal maxillomandibular relation with no tooth contact, as well as 2 wax techniques with an anterior hard stop, which has been proven to be a reliable technique.⁹¹⁻⁹³ Then, this maxillomandibular relation wax recording is used to obtain the dental cast in the articulator, where the face bow has placed the maxilla in its correct position and, according to the HOLTA leveling system, to have the true horizontal as a reference. This procedure, as shown in Figure 4, allows us to be consistent with what we have done in all of our previous static and dynamic records.

Once we have our patient in CSP/CR, we use this opportunity to go one step forward in our protocol, and we perform a true hinge axis clinical recording in all of our orthognathic surgery patients. The need for using a true mandibular hinge axis, specifically when we need to perform a vertical maxillary impaction or any skeletal maxillary movement resulting in a mandibular autorotation, has been studied in the past,

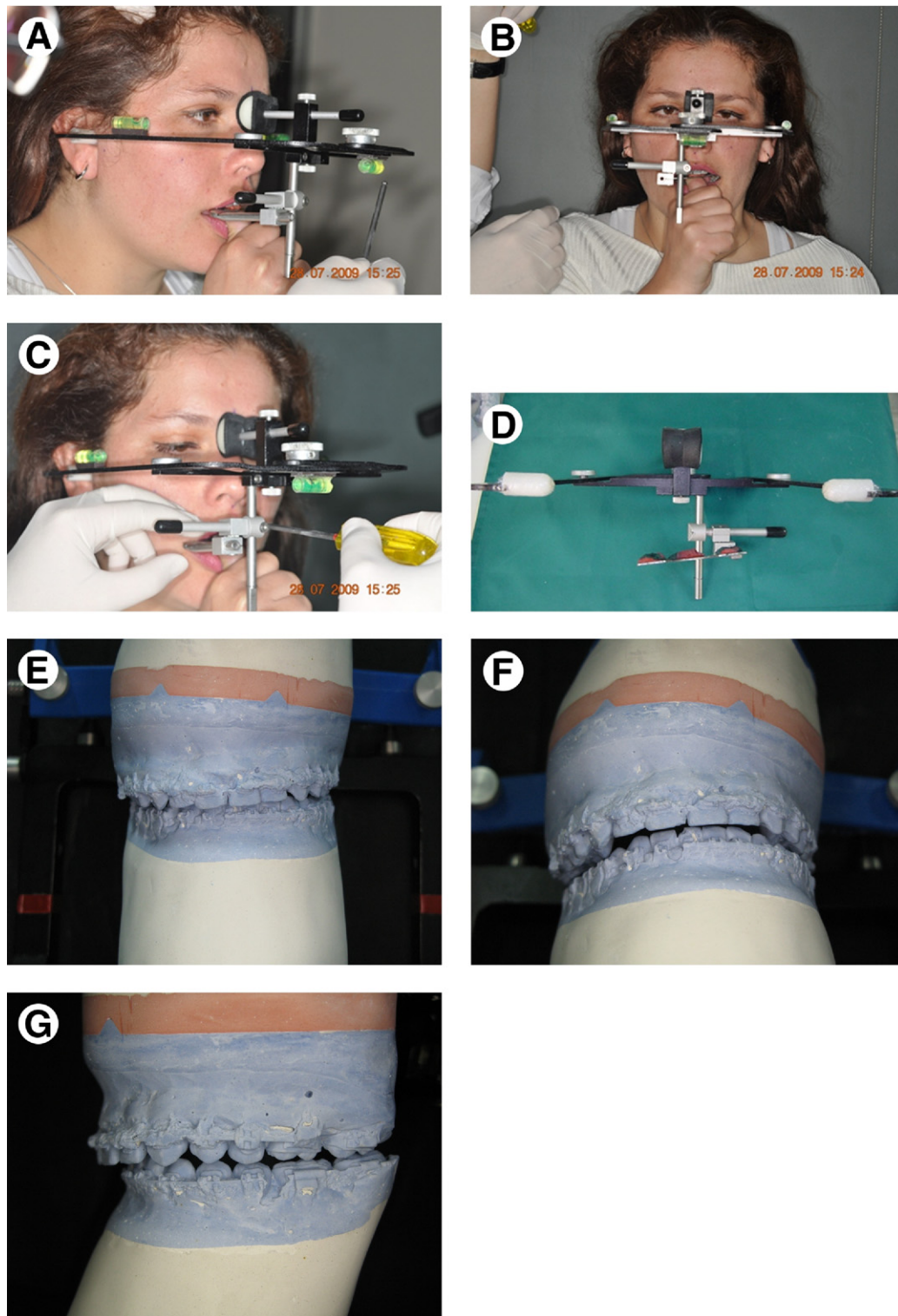


FIGURE 4. Face bow transfer protocol using spirit levels to fix maxillary fork record. *A*, Lateral view of patient at ONHP using spirit levels. *B*, Frontal view. *C*, Maxillary fork fixation to face bow being aligned with bilateral and frontal spirit levels. *D*, Posterior view of face bow recording of maxilla with real canting of occlusal plane. *E-G*, Articulated dental model with proper 3D alignment and mounted according to the true horizontal reference.

Quevedo, Ruiz, and Quevedo. Clinical Protocol for Orthognathic Surgery. J Oral Maxillofac Surg 2011.

particularly in the orthodontics and prosthodontics literature.^{91,94-97} Using the Whip Mix face bow and articulator, Teteruck and Lundeen⁹⁵ found that 75.5% of the approximate hinge axes would fall within a 6-mm radius of the true hinge axis. The results of a study by Wood and Korne⁹⁶ led them to conclude that, given its practicality and reliability, the use of the estimated hinge axis is recommended in orthodontics. However, only the true hinge axis is recommended for the study of mandibular movements, for diagnostic and definitive equilibration of casts, for extensive restorative reconstruction, and for maxillary surgical movements resulting in autorotation of the mandible.^{96,97} In our protocol we clinically record the true hinge axis using a Hinge Axis Locator (code 85301; Almore International, Portland, OR). This procedure takes approximately 25 minutes to perform and is incorporated as part of a whole presurgical records session appointment, which includes clinical photos, determination of the HOLTA fiducial marking for clinical photos and radiography/CBCT imaging. The CSP/CR wax recording and face bow recording are necessary for the dental model montage in the articulator. The whole session takes approximately 1 hour. Using the 3D scenario in our patients, we are exploring the idea of mathematically calculating the true hinge axis, using an extra scan of 2 silicone bites with proper radiopaque markers taken from the semi-adjustable articulator, where the dental models are articulated via the wax recording of CSP/CR and via the horizontal/vertical reference. With this procedure, we strive to develop a skull-dental composite 3D model (virtual articulator), allowing us to study dental and skeletal relations more precisely.

STEP 2: TREATMENT PLANNING

The second aspect to include in the protocol for orthognathic surgery is treatment planning. This planning includes cephalometric prediction tracings (both computerized and manual) and model surgery. The conventional 2D prediction tracing techniques have been broadly included in all of the main surgical textbooks dedicated to orthognathic surgery⁴⁰⁻⁴³ and in the orthodontics literature.^{74,98,99} Each surgeon uses his or her own modifications of the original techniques and methods.¹⁰⁰⁻¹⁰² Like other methods, our own method has been published.^{45,103} Furthermore, these 2D manual methods were the basis for the digital scenario provided by computed tomography.^{1,2,20,21,104-106} In addition, different companies have launched their own software, such as Quickceph, Dolphin, or Nemoceph.¹⁰⁷⁻¹⁰⁹ This software, among several other software programs, allows the clinicians to study and plan their cases on their own computer screen. Our method was adopted by one of these companies.¹¹⁰

Both manual/mechanical and digital/computer methods have the same major problem of being 2D, and for that reason, both systems have the same room for error. In our practice, we have used both methods and found the same results because we always adhered to principles discussed in this article. These principles include the following: using the ONHP; using 1 true horizontal/vertical reference in all records; properly studying dental malocclusion and skeletal deformities using a CSP/CR maxilla-mandible relation and using the true hinge axis; taking images with the soft tissue at rest and with first tooth contact; and calibrating the lateral radiograph with a computer, as well as matching it with the lateral soft tissues taken from the facial photo.

Now, imaging techniques along with the scanner and associated software technology are widely used, and the 3D era started first with cephalometry.^{9,83,104,111,112} In this regard, we appreciate the atlas book of Swennen et al,⁸⁵ which is a great piece of work. Subsequently, 3D treatment planning was researched, and 3D virtual planning is now a reality.^{16,17,20,37-39,113-116} In this evolution of treatment planning for orthognathic surgery, we can recognize one major advantage, which represents a great paradigm shift. We shift from a 2D tools reality toward the use of a proper 3D scenario to plan 3D deformities. Now, when we are expecting a full 3D imaging tool, we should ask for the same principles we have followed in the 2D scenario, because despite its inherent restrictions, they have been the base of predictability and consistency. Thus, whatever skeletal problem our patient has, we will be able not only to see it but also to understand the differences between both sides of the patient's face and plan the appropriate way to treat his or her deformity. Unfortunately, most of the software we have seen in this 3D scenario reproduces the same problems as 2D analysis or 2D imaging techniques. The presence of these problems is particularly true when 3D cephalometry is presented, such as the work by Olszewski et al,^{117,118} in which there are right- and left-side cephalometric landmarks. An average point is used to do the actual analysis, which is exactly what we do when using the 2D techniques. Therefore we will have to wait until we have a real full 3D scenario to work up our patients.

The next step in treatment planning for the orthognathic surgery protocol is the model surgery. The first item for us to establish is that, in pursuing predictability, we use the Erickson platform⁴⁶ to continue having a horizontal/vertical true reference. In addition, we always perform the maxillary surgery first, which can be planned more precisely than the mandible from the usual 2D prediction tracings, and we let the model surgery tell us what we should do in the mandible. As with the chin, we take what we had decided in the prediction tracing and correlate the movement we expected to have with how much the same point moved

in the anatomic model surgery. We adjust the final chin surgery according to these findings.

Many authors have shown that, in this step, there is much room for error.^{73,119-122} The main reasons for this error are the restricted anatomic and functional replications of the semiadjusted articulator, which causes a difficult and arbitrary transfer of the maxilla with a face bow that uses an axio-orbital plane as a reference. The other cause for errors is the unrealistic replication of the skeletal anatomy with a plaster dental model, which means that the surgeon cannot duplicate or identify the direction or the amount of movement (in millimeters) that the different parts of the involved bony structures will undergo at the time of surgery. Although this is true, in our practice, we use the spirit level in the face bow to transfer the maxilla using the true horizontal/vertical reference, as in all of our records. This method is consistent with the use of the Erickson platform,^{46,50} which maintains the horizontal/vertical plane as the standard reference. In doing this, we are able to be aware of the directional changes we are planning with our surgical procedures. The other way for us to achieve more precision with our model surgery is to work with what we call anatomic sets of models. To make these models, we replicate in the plaster the exact vertical and horizontal position of what we call key skeletal structures in our treatment planning. These key structures are the anterior nasal spine (ANS), as it correlates to the upper lip support, and the nasolabial angle. The next key structure is the so-called chin point, because we should know what needs to be done with the patient's chin. Then, laterally, we measure and mark on our anatomic model a point that represents the inferior border of the mandible at the site of sagittal split osteotomies bilaterally; thus we should be more aware of the movement of both the proximal and distal segments and the type of gap or overlapping that will be present during surgery at these points. The method we use to replicate all these skeletal key structures uses the Erickson platform to measure the anterior-posterior and vertical position of the upper incisor related to the ANS, as measured on the lateral cephalometric radiograph and its tracing, and then, we cut or remodel the plaster to place the ANS reference. We use the same procedure we used to anatomically mark the chin point, using the lower incisor and the anterior end of the chin osteotomy line as the reference point, and for the bilateral body references, we used the first molars and the inferior border of the related mandible. As in surgery, we use a modified version of the Le Fort I step osteotomy, previously described by Epker and Fish,⁴³ and we use a reference point 35 mm above the canines and 25 mm above the first upper molars. We try to avoid measuring any other markings or reference points (Fig 5). With this anatomic marking of the key structures, we gain better knowledge of the skeletal movements that we will observe at the time of surgery.

We maintain the direction of the horizontal/vertical reference in every step of this protocol, and the amount of movement we want to occur in our patient is also better approximated with the described anatomic models. Thus we take model surgery very seriously. For us, it is a matter of trust. We allow up to 0.25 mm of adjusted range of error.

As with the model surgery, in the 3D scenario, we have been working on the segmentation of the osteotomies to create a more realistic scenario when we move the osteotomized segments. We believe that, if we are not able to reproduce the exact relations of the distal and proximal segments, we will end up with a different result at the time of surgery. Although this bony segment relation has major implications with regard to bilateral split ramus osteotomy, it is also very important for the Le Fort I osteotomy, especially when we perform segmental mobilizations.

Efforts to exactly replicate the human masticatory system with a mechanical apparatus were long ago abandoned by us. Even the most adjustable articulator possible will never replicate our patient. We explored a virtual articulator with its mechanical version using stereolithography of parts of the skull, which fully replicates the maxilla, mandible, and TMJ anatomy 3-dimensionally. This approach can be used in a metallic frame to better study the malocclusion and the ideal occlusal relations we need to reproduce as a final outcome in our patient. Of course, it is a matter of time for the technology to give us the pending solutions. Then, we will not use any mechanical devices or plaster models because everything will be done virtually in some central office as a service of an imaging technology laboratory.

Precise replication of the masticatory system is one of the expected outcomes of the 3D era; however, we are looking for simulation, not only replication or prediction, and that can only be achieved through a computer-generated full anatomic model and a virtual articulator. Given the technical problems that still exist in replicating teeth and functional occlusion,³⁸ currently, we still need to continue using plaster models and a mechanical articulator to fabricate the surgical splints to transfer our treatment planning to our patient at the time of surgery.

STEP 3: TRANSFERRING FINAL PLAN TO OPERATING FIELD

Finally, the surgical splints—both intermediate and final—will need to be made. Those splints should be the end result of the whole process, and they should come easily. The same results should occur in the 3D virtual scenario. With the segmentation and definition of tooth anatomy that we see in the near future with the right technology, we could simulate much better how we will operate on patients with much more

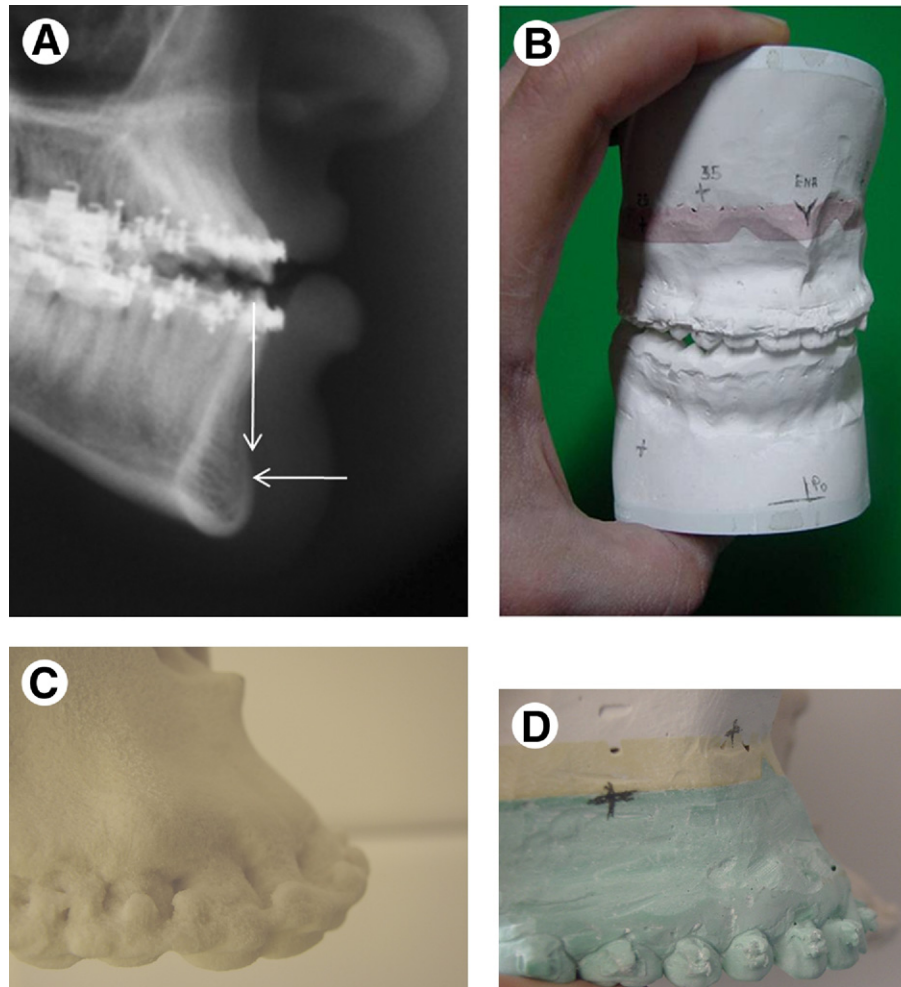


FIGURE 5. Anatomizing plaster dental model to better reproduce skeletal key structure movement at model surgery. A, Measurements are taken from the lateral radiograph using horizontal/vertical reference. B, Upper and lower anatomized model. C, D, Comparison between plaster model and stereo lithography model.

Quevedo, Ruiz, and Quevedo. Clinical Protocol for Orthognathic Surgery. J Oral Maxillofac Surg 2011.

precision. The surgical splints should be predictable and consistent with the desired result. The actual result of our type of model surgery has good predictability, but because this method is just an improved 2D method, this approach will never be exact.

A computer-generated surgical splint has not yet been proven to be fully reliable in complex double-jaw surgical cases.^{35-39,73,123,124} In our opinion, the mistakes among the different groups of researchers mainly replicate the same problem we found with the conventional 2D protocols.

Discussion

Technology, research or researchers, and dissemination of new knowledge (scientific publications) are not to be blamed but are to be congratulated for this rapid race for the latest application of various inventions. The clinician is responsible for finding the best possible care

available, which is hopefully based on evidence-based medical-dental practice. We just need to remember that what is in the scientific literature and has not been proven is not necessarily good or bad. Although evidence-based practices are recommended when available, practices that are not evidence based are not necessarily bad or wrong, like some authors claim.¹²⁵ Most of the time, these practices just lack relevant properly designed scientific literature.

We have always thought that diagnosis is essential for everything that clinicians do. In 3D virtual technology, we have an enormous tool that allows us to more closely replicate the actual patient. Incorporating 3D cephalometry is essential, but we think we still have much to do before achieving the right perspective in using this new tool. The 3D cephalometric analyses we have seen in the most recent literature duplicate some of the problems that we experienced for a long time with conventional 2D analysis. In the 3D cephalometric analysis of

Swennen et al,⁸⁵ measurements were calculated between landmarks on 2D cephalograms.⁹ Treil et al¹²⁶ developed a 3D cephalometric analysis based on a complicated reference frame constructed on 8 landmarks belonging to the trigeminal system. In addition, this analysis does not propose the use of any sagittal plane. Bettega et al, cited by Olszewski et al,¹¹⁷ proposed an automatic 3D CT cephalometric analysis based on a simplified version of Jean Delaire's architectural and structural 2D cephalometric analysis.¹⁰⁰ The analysis and software presented by Olszewski et al,^{117,118} who also presented an original 3D cephalometric analysis based on a transformation of Delaire's classical 2D cephalometric analysis, surprised us the most. Their conclusions were as follows: "We demonstrated that the three-dimensional analysis gives the same results as two-dimensional analysis using the same skull." This conclusion is surprising because we would expect many differences between a 2D and a 3D cephalometric study and to gain a much better understanding of the skull structures with 3D analysis. If our understanding is not improved with 3D analysis, we wonder why this method should be used. Perhaps the data necessary to create 3D cephalometry based on 2D cephalograms is still lacking. Swennen et al⁸⁵ have suggested gathering these data through the Internet, because all of the data could be easily collected, and multicenter studies should give us extensive access to valid information.

As per the functional records and the appropriate way to establish the skeletal and dental deformity, we believe in the diagnosis and the treatment planning from TMJ centric relation, which has proved to be the most reliable maxillomandibular relation functionally. We have done an extensive review of the literature, and there are numerous authors who believe that a centric relation is the best relation in the TMJ for functional stability.^{91,127-147} In addition, it is critical to have a well-seated condyle for the diagnosis of the malocclusion because this position is considered to be the most reliable and reproducible reference point for accurately recording the relation of the mandible to the maxilla.^{92,127,129,131,137} Therefore a determination of the seated condylar position (SCP/CR) is a prerequisite for the analysis of dental and skeletal relations. Furthermore, for the correct diagnosis of the dentofacial deformity and treatment,^{44,45,148} we bring our orthognathic patients into their TMJ centric relation; this treatment has been part of our protocol for at least a decade.¹⁴⁹ Our method of achieving this SCP/CR relation in our patients is also a matter of continuously reviewing the relevant literature. Many studies have shown that the neuromusculature positions the mandible to achieve maximal intercuspation, regardless of the position of the condyles.^{94,150-157} Therefore the occlusion dictates condylar position. The resultant muscle function can be too dominant so that the acquired

mandibular position will often be mistaken by the clinician for the seated condylar position. Therefore clinical mandibular manipulation, which many surgeons use to examine their patients, is unreliable in determining the seated condylar position because of the effects of the neuromusculature. Neuromuscular deprogramming is the key to reproducibility.^{94,127,130,131,139,150-156,158-166} Therefore we were obligated to perform neuromuscular deprogramming in all of our orthognathic surgery patients, and the time involved in this presurgical preparation depends on the type of skeletal deformity, as shown in our studies.¹⁴⁹ Splint therapy has been proven effective in deprogramming the neuromusculature.^{94,130,139,151-155,157,159,160,162,163}

Technology promises to improve our treatment outcomes. Technology is developed to serve the clinicians who are using it and applying it. However, one should be cautious of turning to the latest technologic development too quickly, without first obtaining a base of knowledge and understanding of what has been proven. We should not serve technology, or use our patients to do so, because that is not what medicine is about.

Our group is working to create a total virtual working environment in orthognathic surgery. We call this environment SAIEMSE, from its name in Spanish (Sistema de Apoyo Integral para el Estudio y Manejo de las alteraciones esqueléticas y dentarias, estéticas y funcionales del Sistema Estomatognático). In English, this translates to "Comprehensive Aids System for the Study and Management of the Skeletal, Dental, Aesthetic or Functional Abnormalities of the Gnathic System." This environment represents a combination of software applications, which work as a total assistant within a virtual environment in which the surgeon or any other person follows the software instructions to introduce the patient's data, just like any of the current 2D computed cephalograms. The system includes a virtual articulator, which in fact should not be a mechanical device trying to replicate our patients' functions but is our actual patient's skull, joints, and teeth moving as we command. We are sure this is just the beginning of what we will have available to work with until software capable of assembling DICOM (Digital Imaging and Communications in Medicine) files, coming from CBCT, magnetic resonance imaging, single photon emission computed tomography, ultrasound, and other sources, is developed. We are confident in the technologies that will be available in the near future, such as a full virtual patient to study and on which to do our workup to simulate our treatments. It is also true that, whatever we will have available and decide to use, it must be based on principles that should never change. In the SAIEMSE project the software performs the analysis and makes a problem list at every step of the study (facial analysis, model analyses, imaging, cephalometrics, and so on). The software will produce

a chart and checklist whenever necessary and obtain a working diagnosis to enter for the next step, which is treatment planning. This includes treatment simulations that can be printed or displayed. This training scenario depends on the user's wishes to perform everything by herself or himself or in a centralized office, where someone else will perform these tasks.

Orthognathic surgery, in conjunction with surgical orthodontics, has been shown to be the best way to treat dentofacial deformities. When appropriately performed, it is predictable and provides consistently good results. To achieve these results, surgeons have examined and practiced protocols for diagnosis and treatment planning and consider those at least as important as the surgery itself. Predictability comes from consistent outcomes and makes these protocols reliable. Whether we are using the conventional manual and mechanical way to study and plan our cases or we are using a digital method, such as virtual 3D technology, we must perform these methods correctly. For us, these protocols mean that, for the static diagnosis part, we should have our patient in ONHP to take our clinical set of photos in a repeatable standardized manner and to know up to what angle to orient our patient's NHP, whenever it should be needed, using the spirit level. To achieve consistency in all of our records, we should have a unique reference, which in our case is the true horizontal/vertical. For this reason, we transport this reference to the patient's skin through the HOLTA system, which allows us not only to check the patient's orientation in the clinical setting but also to continue using the same reference with the fiducial markings. So, the patient is brought to the radiography laboratory for either conventional frontal and lateral films or CBCT scan (or both). At the time when we perform our manual or digital cephalometric tracing, we use consistent radiographs and clinical photos that relate to each other. As soon as we diagnose our patient, we are ready to perform our treatment planning; we carry it out with the same true horizontal reference that guides us in the movement we want to transport to the model surgery. Therefore we will plan the surgery manually or virtually to decide how many millimeters we will move the jaw in a specific direction. Here, we have to realize that we are planning for a 3D problem in a 2D manner, and we will not expect the prediction tracing to properly plan an asymmetric or syndrome case. Actually, to avoid misinterpretation from a 2D tool such as the lateral view we use, we let the model surgery, which is 3D, provide the exact surgical specifications for us to perform in the mandible. The prediction tracing describes the surgery we will perform in the maxilla. However, even in the maxilla, if we have an asymmetric case, we cannot trust our lateral tracing. First, we should level the occlusal plane from the frontal view to determine the lateral impaction/descending movements of the posterior maxilla and let

the model surgery tell us what to do with the mandible. The need to plan a 3D problem with a true 3D tool is one of the major motivations for developing 3D virtual planning. Whatever we decide to do, we need to perform this in the laboratory with the model surgery. We are in a good position because we have specifically anatomized sets of articulated models that have maintained the same horizontal reference we use in clinical/radiographic records. Furthermore, the maxilla/mandible relation has been captured by use of CSP/CR considerations and by use of the true hinge axis to rotate the maxillary-mandible complex. In other words, all of the patient's records are consistent among themselves and with each patient's real dentofacial deformity. Finally, the fabrication and use of surgical splints—both intermediate and final—just require practice. Those splints should be the end result of the whole process, and they should come easily. The only requirement for this result to happen is that all of the previous steps are taken following the same principles already mentioned.

The principles are the same for both the conventional manual/mechanical method and the new 3D virtual method. The goal is still to achieve the best outcome possible for optimal patient care.

References

- Halazonetis DJ: From 2-dimensional cephalograms to 3-dimensional computed tomography scans. *Am J Orthod Dentofacial Orthop* 127:627, 2005
- Hatcher DC, Aboudara CL: Diagnosis goes digital. *Am J Orthod Dentofacial Orthop* 125:512, 2004
- Ono I, Ohura T, Narumi E, et al: Three-dimensional analysis of craniofacial bones using three-dimensional computer tomography. *J Craniomaxillofac Surg* 20:49, 1992
- Altobelli DE, Kikinis R, Mulliken JB, et al: Computer-assisted three-dimensional planning in craniofacial surgery. *Plast Reconstr Surg* 92:576, 1993
- Carls FR, Schuknecht B, Sailer HF: Value of three-dimensional computed tomography in craniomaxillofacial surgery. *J Craniofac Surg* 5:282, 1994
- Cevidane LH, Bailey IJ, Tucker GR Jr, et al: Superimposition of 3D cone-beam CT models of orthognathic surgery patients. *Dentomaxillofac Radiol* 34:369, 2005
- Cevidane LH, Bailey IJ, Tucker SF, et al: T. Three-dimensional cone-beam computed tomography for assessment of mandibular changes after orthognathic surgery. *Am J Orthod Dentofacial Orthop* 131:44, 2007
- Farman AG, Scarfe WC: Development of imaging selection criteria and procedures should precede cephalometric assessment with cone-beam computed tomography. *Am J Orthod Dentofacial Orthop* 130:257, 2006
- Lagravere MO, Major PW: Proposed reference point for 3-dimensional cephalometric analysis with cone-beam computerized tomography. *Am J Orthod Dentofacial Orthop* 128:657, 2005
- Kobayashi K, Shimoda S, Nakagawa Y, et al: Accuracy in measurement of distance using limited conebeam computerized tomography. *Int J Oral Maxillofac Implants* 19:228, 2004
- Lascale CA, Panella J, Marques MM: Analysis of the accuracy of linear measurements obtained by cone beam computed tomography (CBCT-NewTom). *Dentomaxillofac Radiol* 33:291, 2004
- Loubele M, Guerrero ME, Jacobs R, et al: A comparison of jaw dimensional and quality assessments of bone characteristics with cone-beam CT, spiral tomography, and multi-slice spiral CT. *Int J Oral Maxillofac Implants* 22:446, 2007

13. Ludlow JB, Laster WS, See M, et al: Accuracy of measurements of mandibular anatomy in cone beam computed tomography images. *Oral Surg Oral Med Oral Pathol Oral Radiol Endod* 103:534, 2007
14. Moshiri M, Scarfe WC, Hilgers ML, et al: Accuracy of linear measurements from imaging plate and lateral cephalometric images derived from cone-beam computed tomography. *Am J Orthod Dentofacial Orthop* 132:550, 2007
15. Kim SH, Choi YS, Hwang EH, et al: Surgical positioning of orthodontic mini-implants with guides fabricated on models replicated with cone-beam computed tomography. *Am J Orthod Dentofacial Orthop* 131:882, 2007
16. Fuhrmann RAW, Frohberg U, Diedrich PR: Treatment prediction with three-dimensional computer tomographic skull models. *Am J Orthod Dentofacial Orthop* 106:156, 1994
17. Cutting C, Bookstein FL, Grayson B, et al: Three-dimensional computer-assisted design of craniofacial surgical procedures: Optimization and interaction with cephalometric and CT-based models. *Plast Reconstr Surg* 77:877, 1986
18. Cevdanes LHS, Franco AA, Gerig G, et al: Comparison of relative mandibular growth vectors with high-resolution 3 dimensional imaging. *Am J Orthod Dentofacial Orthop* 128: 27, 2005
19. Ferrario VF, Sforza C, Poggio C, et al: Facial three-dimensional morphometry. *Am J Orthod Dentofacial Orthop* 109:86, 1996
20. Hajeer MY, Ayoub AF, Millett DT, et al: Three-dimensional imaging in orthognathic surgery: The clinical application of a new method. *Int J Adult Orthodon Orthognath Surg* 17:318, 2002
21. Lee JY, Han Q, Trotman CA: Three-dimensional facial imaging: Accuracy and consideration for clinical applications in orthodontics. *Angle Orthod* 74:587, 2004
22. Cavalcanti MG, Rocha SS, Vannier MW: Craniofacial measurements based on 3D CT volume rendering: Implications for clinical applications. *Dentomaxillofac Radiol* 33:170, 2004
23. Katsumata A, Fujishita M, Maeda M, et al: 3D CT evaluation of facial asymmetry. *Oral Surg Oral Med Oral Pathol Oral Radiol Endod* 99:212, 2005
24. Guyuron B, Ross RJ: Computer generated model surgery. *J Craniomaxillofac Surg* 17:101, 1989
25. Choi JY, Choi JH, Kim NK, et al: Analysis of errors in medical rapid prototyping models. *Int J Oral Maxillofac Surg* 31:23, 2002
26. Lill W, Solar P, Ulm C, et al: Reproducibility of three-dimensional CT-assisted model production in the maxillofacial area. *Br J Oral Maxillofac Surg* 30:233, 1992
27. Santler G, Kracher H, Ruda C: Indications and limitations of three-dimensional models in craniomaxillofacial surgery. *J Craniomaxillofac Surg* 26:11, 1998
28. Sannomiya EK, Reis SA, Asaumi J, et al: Clinical and radiological presentation and preparation of the prototyping model for pre-surgical planning in Apert's syndrome. *Dentomaxillofac Radiol* 35: 119, 2006
29. Hibi H, Sawaki Y, Ueda M: Three-dimensional model simulation in orthognathic surgery. *Int J Adult Orthodon Orthognath Surg* 12:226, 1997
30. Poukens J, Haex J, Riediger D: The use of rapid prototyping in the preoperative planning of distraction osteogenesis of the cranio-maxillofacial skeleton. *Comput Aided Surg* 8:146, 2003
31. Hassfeld S, Mühling J, Zoller J: Intraoperative navigation in oral and maxillofacial surgery. *Int J Oral Maxillofac Surg* 24: 111, 1995
32. Tsuji M, Nogushi N, Shigematsu M, et al: A new navigation system based on cephalograms and dental casts for oral and maxillofacial surgery. *Int J Oral Maxillofac Surg* 35:828, 2006
33. Theodossy T, Bamber MA: Model surgery with passive robot arm for orthognathic surgery planning. *J Oral Maxillofac Surg* 61:1310, 2003
34. Hassfeld S, Mühling J: Computer assisted oral and maxillofacial surgery: A review and an assessment of technology. *Int J Oral Maxillofac Surg* 30:2, 2001
35. De Vos W, Casselman J, Swennen GRJ: Cone-beam computerized tomography (CBCT) imaging of the oral and maxillofacial region: A systematic review of the literature. *Int J Oral Maxillofac Surg* 38:609, 2009
36. Assael LA: Editorial. *J Oral Maxillofac Surg* 67:2041, 2009
37. Swennen RJ, Mollemans W, Schutyser F: Three-dimensional treatment planning of orthognathic surgery in the era of virtual imaging. *J Oral Maxillofac Surg* 67:2080, 2009
38. Xia J, Gateno J, Teichgraber J: New clinical protocol to evaluate craniomaxillofacial deformity and plan surgical correction. *J Oral Maxillofac Surg* 67:2093, 2009
39. Schendel S, Jacobson R: Three-dimensional imaging and computer simulation for office-based surgery. *J Oral Maxillofac Surg* 67:2107, 2009
40. Epker B, Wolford L: *Dentofacial Deformities: Surgical-Orthodontic Correction*. St Louis, MO, Mosby, 1980
41. Bell WH, Proffitt W, White R: *Surgical Correction of Dentofacial Deformities*. Philadelphia, PA, Saunders, 1980
42. Wolford LM, Hilliari FW, Dugan DJ: *Surgical Treatment Objectives*. St Louis, MO, Mosby, 1985
43. Epker B, Fish L: *Dentofacial Deformities, Integrated Orthodontic and Surgical Correction*. St Louis, MO, Mosby, 1985
44. Quevedo L, Jedes G: *Análisis cefalométricos y estéticos más utilizados*. Facultad de Odontología Universidad de Chile, Santiago, Chile, 2004, pp 117-123
45. Quevedo L: *Predicciones cefalométricas para cirugía ortognática*. Facultad de Odontología Universidad de Chile, Santiago, Chile, 2004, pp 16-23
46. Erickson KL, Bell WH, Goldsmith DH: *Analytical model surgery*, in Bell WH (ed): *Modern Practice in Orthognathic and Reconstructive Surgery*. Philadelphia, PA, Saunders, 1992, pp 154-216
47. Boultault H, Cadenat H: *Stratégie de la décision en chirurgie orthognathique*. *Rev Stomatol Chir Maxillofac* 93:287, 1992
48. Gateno J, Forrest KK, Camp B: A comparison of three methods of face bow transfer recording: Implications for orthognathic surgery. *J Oral Maxillofac Surg* 59:635, 2001
49. Hohl TH: The use of an anatomic articulator in segmental orthognathic surgery. *Am J Orthod* 73:428, 1978
50. Ellis E III: Accuracy of model surgery: Evaluation of an old technique and introduction of a new one. *J Oral Maxillofac Surg* 48:1161, 1990
51. Ellis E III: Bimaxillary surgery using an intermediate splint to position the maxilla. *J Oral Maxillofac Surg* 57:53, 1999
52. Lapp TH: Bimaxillary surgery without the use of an intermediate splint to position the maxilla. *J Oral Maxillofac Surg* 57:57, 1999
53. Bamber MA, Harris M: The role of the occlusal wafer in orthognathic surgery: A comparison of thick and thin intermediate osteotomy wafers. *J Craniomaxillofac Surg* 23:396, 1995
54. Olszewski R, Reyhler H: Les limites de la chirurgie des modèles: Implications théoriques et pratiques. *Rev Stomatol Chir Maxillofac* 105:165, 2004
55. Nattestad A, Vedtofte P: Pitfalls in orthognathic model surgery. The significance of using different reference lines and points during model surgery and operation. *Int J Oral Maxillofac Surg* 23:11, 1994
56. Gil JN, Claus JPD, Manfro R, et al: Predictability of maxillary repositioning during bimaxillary surgery: Accuracy of a new technique. *Int J Oral Maxillofac Surg* 36:296, 2007
57. Walker F, Ayoub AF, Moos KF, et al: Face bow and articulator for planning orthognathic surgery: 1 face bow. *Br J Oral Maxillofac Surg* 46:567, 2008
58. Walker F, Ayoub AF, Moos KF, et al: Face bow and articulator for planning orthognathic surgery: 2 articulator. *Br J Oral Maxillofac Surg* 46:573, 2008
59. Moores CFA, Kean MR: Natural head position, a basic consideration in the interpretation of cephalometric radiographs. *Am J Phys Antropol* 16:213, 1958
60. Moorrees CF: Natural head position—A revival. *Am J Orthod Dentofacial Orthop* 105:512, 1994
61. Peng L, Cooke MS: Fifteen-year reproducibility of natural head posture: A longitudinal study. *Am J Orthod Dentofacial Orthop* 116:82, 1999

62. Lundström F, Lundström A: Natural head position as a basis for cephalometric analysis. *Am J Orthod Dentofacial Orthop* 101:244, 1992
63. Cooke MS, Wei SH: The reproducibility of natural head posture: A methodological study. *Am J Orthod Dentofacial Orthop* 93:280, 1988
64. Gonzalez H, Manns A: Forward head posture: Its structural and functional influence on the stomatognathic system, a conceptual study. *J Craniomandibular Pract* 14:71, 1996
65. Solow B, Sonnesen L: Head posture and malocclusions. *Eur J Orthod* 20:685, 1998
66. Solow B, Tallgren A: Natural head position in standing subjects. *Acta Odontol Scand* 29:591, 1971
67. Usumez S, Uysal T, Orhan M, et al: Relationship between static natural head position and head position measured during walking. *Am J Orthod Dentofacial Orthop* 129:42, 2006
68. Halazonetis DJ: Estimated natural head position and facial morphology. *Am J Orthod Dentofacial Orthop* 121:364, 2002
69. Lundström A, Lundström F, Le Bret LM, et al: Natural head position and natural head orientation: Basic considerations in cephalometric analysis and research. *Eur J Orthod* 17:111, 1995
70. Quevedo L, Jeldes G, et al: Transferencia de la línea bi pupilar a la radiografía panorámica. *Rev Dent Chile* 85:41, 1994
71. Quevedo C: Validación de la Orientación Espacial de la Imagen Obtenida por la Tomografía Computada Cone Beam [thesis]. Santiago, Chile, Universidad de Los Andes, 2008
72. Gateno J, Xia J, Teichgraber J, et al: A new technique for the creation of a computerized composite skull model. *J Oral Maxillofac Surg* 61:223, 2003
73. Gateno J, Xia J, Teichgraber J, et al: The precision of computer-generated surgical splint. *J Oral Maxillofac Surg* 61:814, 2003
74. Ricketts RM, Bench RW, Gugino CF, et al: *Técnica bioprogresiva de Ricketts*. Buenos Aires, Ed Medica Panamericana, 1983
75. Tweed CH: *Clinical Orthodontics*. St Louis, MO, Mosby, 1960
76. Steiner C: Cephalometrics for you and me. *Am J Orthod* 39:729, 1953
77. Sassouni V, Forrest A (eds): *Orthodontics in Dental Practice*. St Louis, MO, Mosby, 1971
78. Bimler HP: Bimler therapy. Part I. Bimler cephalometric analysis. *J Clin Orthod* 19:501, 1985
79. Ricketts RM: Cephalometric analysis and synthesis. *Angle Orthod* 31:141, 1961
80. Burstone CJ, James RR, Legan H, et al: Cephalometrics for orthognathic surgery. *J Oral Surg* 36:269, 1978
81. Enlow DH: *Handbook of Facial Growth*. Philadelphia, PA, Saunders, 1975
82. Delaire J: Quelques pièges dans les interprétations des téléradiographies céphalométriques. *Rev Stomatol Chir Maxillofac* 85:176, 1984
83. Bookstein FL, Grayson B, Cutting CB, et al: Landmarks in three dimensions: Reconstruction from cephalograms versus direct observation. *Am J Orthod Dentofacial Orthop* 100:133, 1991
84. Nakasima A, Terajima M, Mori N, et al: Three-dimensional computer generated head model reconstructed from cephalograms, facial photographs, and dental cast models. *Am J Orthod Dentofacial Orthop* 127:282, 2005
85. Swennen GJ, Schuytser FA, Hausamen JE (eds): *Three Dimensional Cephalometry: A Color Atlas and Manual*. Berlin, Springer, 2005
86. Grayson BH, Cutting C, Bookstein FL, et al: The three-dimensional cephalograms: Theory, technique and clinical application. *Am J Orthod Dentofacial Orthop* 94:327, 1988
87. Canyon State Supply, Hanau articulators and facebows. Available from: URL: http://www.canyonstatedentalsupply.com/hanau_articulators.htm. Accessed December 22, 2010
88. Whip Mix manual. Available from: URL: <http://www.whipmix.com/product.aspx>. Accessed December 22, 2010
89. Panadent Articulators and System. Available from: http://www.panadent.com/html/body_articulators_systems.html. Accessed December 22, 2010
90. SAM Dental Diagnostic Instrument system. Available from: URL: http://www.sam-dental.de/pages/engl_prodinfor.html. Accessed December 22, 2010
91. Crawford SD: The relationship between condylar axis position as determined by the occlusion and measured by the CPI instrument and signs and symptoms of TM joint dysfunction. *Angle Orthod* 69:103, 1999
92. Slavicek RJ: Clinical and instrumental functional analysis for diagnosis and treatment planning, part IV: Instrumental analysis of mandibular casts using the mandibular position indicator. *J Clin Orthod* 22:566, 1988
93. Cordray FE: Centric relation treatment and articulator mountings in orthodontics. *Angle Orthod* 66:153, 1996
94. Williamson EH, Evans DL, Barton W, et al: The effect of biteplane use on terminal hinge axis location. *Angle Orthod* 47:25, 1977
95. Teteruck WR, Lundeen HC: The accuracy of an ear facebow. *J Prost Dent* 16:1039, 1966
96. Wood DP, Korne PH: Estimated and true hinge axis: A comparison of condylar displacements. *Angle Orthod* 62:167, 1992
97. Cordray FE, Michael BF: A three-dimensional analysis of models articulated in the seated condylar position from a deprogrammed asymptomatic population—A prospective study—Part I. Presented at the American Association of Orthodontists 103rd Annual Session, Honolulu, HI, May 4, 2003
98. Gregoret J: *Ortodoncia y Cirugía Ortognática Diagnostico y Planificación*. Barcelona, Espaxs, 2003
99. Gregoret J, Tuber E, Escobar H: *Arco Recto*. Argentina, NM, Madrid, Spain, Ediciones, 2003
100. Delaire J: L'analyse architecturale et structurale cranio-faciale (de profil). Principes théoriques. Quelques exemples d'emploi en chirurgie maxillo-faciale. *Rev Stomatol* 79:1, 1978
101. Arnet GW, Bergman RT: Facial keys to orthodontic diagnosis and treatment planning—Part I. *Am J Orthod Dentofacial Orthop* 103:299, 1993
102. Arnet GW, Bergman RT: Facial keys to orthodontic diagnosis and treatment planning—Part II. *Am J Orthod Dentofacial Orthop* 103:395, 1993
103. Quevedo L: *Planejamiento de Tratamento em Cirurgia Ortognata*. San Pablo, Brazil, Editora Pancast, 2000
104. Adams GL, Gansky SA, Miller AJ, et al: Comparison between traditional 2-dimensional cephalometry and a 3-dimensional approach on human dry skulls. *Am J Orthod Dentofacial Orthop* 126:397, 2004
105. Richtsmeier JT, Paik CH, Elfert PC, et al: Precision, repeatability and validation of the localization of cranial landmarks using computer tomography scans. *Cleft Palate Craniofac J* 32:217, 1995
106. Delaire J, Schendel SA, Tulasne JF: An architectural and structural craniofacial analysis: A new lateral cephalometric analysis. *Oral Surg Oral Med Oral Pathol* 52:226, 1981
107. Quick Ceph System. Available from: URL: <http://www.quickceph.com/company/>. Accessed December 27, 2010
108. Dolphin Imaging 11. Available from: URL: http://www.dolphinimaging.com/imaging/TREATMENT_PLANNING.pdf. Accessed December 27, 2010
109. Nemotec. Available from: URL: <http://www.nemotec.com/>. Accessed December 27, 2010
110. Nemoceph. Available from: URL: <http://www.nemotec.com/es/clinical/nemoceph/VTO.htm>. Accessed December 27, 2010
111. Kusnoto B, Evans CA, BeGole EA, et al: Assessment of 3-dimensional computer-generated cephalometric measurements. *Am J Orthod Dentofacial Orthop* 116:390, 1999
112. Swennen GR, Schuytser F, Barth EL, et al: A new method of 3-D cephalometry. Part I: The anatomic Cartesian 3D reference system. *J Craniofac Surg* 17:314, 2006
113. Moss JP, Grindrod SR, Linney AD, et al: A computer system for the interactive planning and prediction of maxillofacial surgery. *Am J Orthod Dentofacial Orthop* 94:469, 1988
114. Troulis MJ, Everett P, Seldin EB, et al: Development of a three-dimensional treatment planning system based on computer tomographic data. *Int J Oral Maxillofac Surg* 31:349, 2002

115. Okumura H, Chen LH, Tsutsumi S, et al: Three-dimensional virtual imaging of facial skeleton and dental morphologic condition for treatment planning in orthognathic surgery. *Am J Orthod Dentofacial Orthop* 116:126, 1999
116. Chen LH, Chen WH: Three-dimensional computer-assisted simulation combining facial skeleton with facial morphology for orthognathic surgery. *Int J Adult Orthodon Orthognath Surg* 14:140, 1999
117. Olszewski R, Zech F, Cosnard G, et al: 3D CT cephalometric craniofacial analysis: Experimental validation in vitro. *Int J Oral Maxillofac Surg* 36:828, 2007
118. Olszewski R: Three-dimensional computed tomography based craniofacial cephalometric analysis: Concept, software, and experimental validations [doctoral thesis]. Université Catholique de Louvain Faculté de Médecine Service de Stomatologie et Chirurgie Maxillo-Faciale, Brugges, Belgium, 2007
119. Gateno J, Xia J, Teichgraber J, et al: Clinical feasibility of computed-aided surgical simulation (CASS) in the treatment of complex craniomaxillofacial deformities. *J Oral Maxillofac Surg* 65:728, 2007
120. Swennen GRJ, Barth EL, Eulzer C, et al: The use of a new 3D splint and double CT scan procedure to obtain an accurate anatomic virtual augmented model of the skull. *Int J Oral Maxillofac Surg* 36:146, 2007
121. Santler G: 3D Cosmos: A new 3D model based computerized operation simulation and navigation system. *J Craniomaxillofac Surg* 28:287, 2000
122. Swennen GRJ, Mommaerts MY, Abeloos J, et al: The use of a wax bite wafer and a double computed tomography scan procedure to obtain a three-dimensional augmented virtual skull model. *J Craniofac Surg* 18:533, 2007
123. Amira software. Available from: URL: <http://www.tgs.com>. Accessed January 4, 2010
124. Maxilim software. Available from: URL: <http://www.medicim.be>. Accessed January 4, 2010
125. Rinchuse D, Kandasamy S: Articulator in orthodontics. *Am J Orthod Dentofacial Orthop* 129:299, 2006
126. Treil J, Casteigt J, Borianne P, et al: L'équilibre architectural de la face: Un concept céphalométrique 3D. *Rev Stomatol Chir Maxillofac* 100:111, 1999
127. Howat AP, Capp NJ, Barrett NVJ: A Color Atlas of Occlusion and Malocclusion. St Louis, MO, Mosby, 1991
128. Ramfjord SP, Ash MM: Occlusion (ed 3). Philadelphia, PA, Saunders, 1983
129. Okeson JP: Management of TM Disorders and Occlusion (ed 3). St Louis, MO, Mosby, 1993, p 113
130. Roth RH: The maintenance system and occlusal dynamics. *Dent Clin North Am* 20:761, 1976
131. Dawson PE: Evaluation, Diagnosis, and Treatment of Occlusal Problems (ed 2). St Louis, MO, Mosby, 1989, pp 28-33, 41-45, 132, 590-591
132. Dawson PE: New Definition for Relating Occlusion to Varying Conditions of the TM Joint. St Louis, MO, Mosby, 1995, pp 619-627
133. Williamson EH: The role of craniomandibular dysfunction in orthodontic diagnosis and treatment planning. *Dent Clin North Am* 27:541, 1983
134. Hylander WL: Functional anatomy, in Sarnat BG, Laskin DM (eds): The Temporomandibular Joint (ed 3). Springfield, IL, Thomas, 1979, p 60-91
135. Rees L: The structure and function of the mandibular joint. *Br Dent J* 156:125, 1954
136. Moffet BC Jr, Johnson LC, McCabe JB, et al: Articular remodeling in the adult human temporomandibular joint. *Am J Anat* 115:119, 1969
137. Lundeen HC, Gibbs CH: Advances in occlusion, in Postgraduate Dental Handbook, Series Vol 14. Gainesville, FL, University of Florida. John Wright Publisher, 1982, pp 7-10
138. Stuart CE: Good occlusion for natural teeth. *J Prosth Dent* 14: 716, 1964
139. Posselt V: Physiology of Occlusion and Rehabilitation (ed 2). Oxford, Blackwell Scientific Publications, 1968
140. Huffman RW, Regenos JW: Principles of Occlusion. Columbus, OH, Hand R Press, 1978
141. Gilboe DB: Centric relation as the treatment position. *J Prosth Dent* 53:685, 1983
142. Thompson JR: Function—The neglected phase of orthodontics. *Angle Orthod* 26:129, 1956
143. Ricketts RM: Provocations and Perceptions in Cranio-facial Orthopedics, Dental Science, and Facial Art. Denver, CO, Rocky Mountain Orthodontics, 1989, p 612
144. Roth RH: Occlusion and condylar position. *Am J Orthod* 107:315, 1995
145. Hicks ST, Wood DP: Recording condylar movement with two facebow systems. *Angle Orthod* 66:293, 1996
146. Slavicek R: Interviews on clinical and instrumental functional analysis for diagnosis and treatment planning, part II. *J Clin Orthod* 22:430, 1988
147. Roth RH, Rolfs DA: Functional occlusion for the orthodontist. Part II. *J Clin Orthod* 15:100, 1981
148. Quevedo L: CR & surgical techniques in orthognathic surgery. Presented at the Roth Williams International Society of Orthodontists Annual Conference (RWISO), Denver, CO, May 2008
149. Quevedo L: Neuromuscular pacification in treatment planning for orthognathic surgery. Presented at the XVI Congress of the European Association of Cranio-Maxillo-Facial Surgery (EACMFS), Helsinki, September 1998
150. Williamson EH, Steinke RM, Morse PK, et al: Centric relation: A comparison of muscle-determined position and operator guidance. *Am J Orthod* 77:133, 1980
151. Girardot RA: The nature of condylar displacement in patients with TM pain-dysfunction. *Orthod Review* 1:16, 1987
152. Karl PJ, Foley TF: The use of a deprogramming appliance to obtain centric relation records. *Angle Orthod* 69:117, 1999
153. Lundeen H: Centric relation records—The effects of muscle action. *J Prosth Dent* 31:244, 1972
154. Solberg WK, Clark GT, Rugh JD: Nocturnal EMG evaluation of bruxism patients undergoing short-term splint therapy. *J Oral Rehabil* 2:215, 1975
155. Beard CC, Clayton JA: Effects of occlusal splint therapy on TMJ dysfunction. *J Prosth Dent* 44:324, 1980
156. Troelstrup B, Moller E: Electromyography of the temporalis and masseter muscles in children with unilateral crossbite. *Scand J Dent Res* 78:425, 1970
157. Calagna LS, Silverman SI, Garfinkel L: Influence of neuromuscular conditioning on centric registrations. *J Prosth Dent* 30:598, 1973
158. Roth RH: TM pain-dysfunction and occlusal relationships. *Angle Orthod* 43:136, 1973
159. Huffman RW, Regenos JW: Principles of Occlusion, Laboratory and Clinical Teaching Manual. Department of Operative Dentistry, Ohio State University, Columbus, OH, 1973
160. Okeson J: Interdisciplinary treatment: TMJ. Presented at the American Association of Orthodontists Annual Session, Dallas, TX, 1999
161. Okeson JP: When Is Orthodontic Therapy Indicated for the Management of TMD? [audiotape]. Birmingham, AL, Practical Reviews in Orthodontics, Educational Reviews, 1998
162. Coulson R: Should the phenomena of muscle splinting be ruled out prior to making an orthodontic diagnosis? Presented at the AAO Convention, St Louis, MO, May 9-13, 1992
163. Greco PM, Vanarsdall RL: An evaluation of anterior temporalis and masseter muscle activity in appliance therapy. *Angle Orthod* 69:141, 1999
164. Shafagh I, Amirloo R: Replicability of chin-point guidance and anterior deprogrammer for recording centric elation. *J Prosth Dent* 42:402, 1979
165. Dyer EH: Importance of a stable maxillomandibular relation. *J Prosth Dent* 30:241, 1973
166. Okeson JP: Management of TM Disorders and Occlusion (ed 2). Treatment of Chronic Mandibular Hypomovility. St Louis, MO, Mosby, 1989, pp 453-478