

The six keys to normal occlusion

Lawrence F. Andrews, D.D.S.

San Diego, Calif.

This article will discuss six significant characteristics observed in a study of 120 casts of nonorthodontic patients with normal occlusion. These constants will be referred to as the "six keys to normal occlusion." The article will also discuss the importance of the six keys, individually and collectively, in successful orthodontic treatment.

Orthodontists have the advantage of a classic guideline in orthodontic diagnosis, that is, the concept given to the specialty a half-century ago by Angle that, as a *sine qua non* of proper occlusion, the cusp of the upper first permanent molar must occlude in the groove between the mesial and middle buccal cusps of the lower first permanent molar.

But Angle, of course, had not contended that this factor alone was enough. Clinical experience and observations of treatment exhibits at national meetings and elsewhere had increasingly pointed to a corollary fact—that even with respect to the molar relationship itself, the positioning of that critical mesiobuccal cusp within that specified space could be inadequate. Too many models displaying that vital cusp-embrasure relationship had, even after orthodontic treatment, obvious inadequacies, despite the acceptable molar relationship as described by Angle.

Recognizing conditions in treated cases that were obviously less than ideal was not difficult, but neither was it sufficient, for it was subjective, impressionistic, and merely negative. A reversal of approach seemed indicated: a deliberate seeking, first, of data about what was significantly *characteristic* in models which, by professional judgment, needed *no* orthodontic treatment. Such data, if systematically reduced to ordered, coherent paradigms, could constitute a group of referents, that is, basic standards against which deviations could be recognized and measured. The concept was, in brief, that if one knew what constituted "right," he could then directly, consistently, and methodically identify and quantify what was wrong.

A gathering of data was begun, and during a period of four years (1960 to 1964), 120 nonorthodontic normal models were acquired with the cooperation of local dentists, orthodontists, and a major university. Models selected were of teeth which (1) had never had orthodontic treatment, (2) were straight and pleasing in appearance, (3) had a bite which looked generally correct, and (4) in my judgment would not benefit from orthodontic treatment.

The *crowns* of this multisource collection were then studied intensively to ascertain which characteristics, if any, would be found consistently in all the models. Some theories took form but soon had to be discarded; others required modification and then survived. Angle's molar cusp groove concept was validated still again. But there was growing realization that the molar relationship in these healthy normal models exhibited two qualities when viewed buccally, not just the classic one, and that the second was equally important.

Other findings emerged. Angulation (mesiodistal tip) and inclination (labiolingual or

buccolingual inclination) began to show predictable natures as related to individual tooth types. These 120 non-orthodontic normals had no rotations. There were no spaces between teeth. The occlusal plane was not identical throughout the battery of examples but fell neatly into so limited a range of variation that it clearly was a differential attribute.

Tentative conclusions were reached, and six characteristics were formulated in general terms. However, a return was needed now to the complementary bank of information made available by many of this nation's most skilled orthodontists—the treated cases on display at national meetings. Eleven hundred fifty of these cases were studied, from 1965 to 1971, for the purpose of learning to what degree the six characteristics were present and whether the absence of any one permitted prediction of other error factors, such as the existence of spaces or of poor posterior occlusal relations.

American orthodontic treatment can be considered to be about the finest in the world. Most of our leaders in this field spent 10 or 15 years in successful practice before submitting their work at these national meetings. There can be no disparagement of their competency. The fact that some range of excellence was found within the 1,150 models implies no adverse criticism; instead, that finding simply reflected the present state of the art. Few would claim that orthodontics, even on the high level seen at the meetings, has reached its ultimate development. Last to make such a claim would be the masters whose work is there displayed for closest scrutiny by peers as well as by neophytes.

Having long since benefited from the good examples offered by such men, I at this point in the research assumed that a comparison of the best in treatment results (the 1,150 treated cases) and the best in nature (the 120 nonorthodontic normals) would reveal differences which, once systematically identified, could provide significant insight on how we could improve ourselves orthodontically. Deliberately, we sought those differences.

The six keys

The six differential qualities were thus validated. They were established as meaningful not solely because all were present in each of the 120 nonorthodontic normals, but also because the *lack* of even one of the six was a defect predictive of an incomplete end result in treated models.

Subsequent work elaborated and refined the measurements involved and provided statistical analysis of the findings. These matters will be reported in future papers. For the present article, a summary is offered chiefly in verbal form.

The significant characteristics shared by all of the nonorthodontic normals are as follows:

1. *Molar relationship.* The distal surface of the distobuccal cusp of the upper first permanent molar made contact and occluded with the mesial surface of the mesiobuccal cusp of the lower second molar. The mesiodistal cusp of the upper first permanent molar fell within the groove between the mesial and middle cusps of the lower first permanent molar. (The canines and premolars enjoyed a cusp-embasure relationship buccally, and a cusp fossa relationship lingually.)
2. *Crown angulation, the mesiodistal "tip" (Fig. 4).* In this article, the term *crown angulation*

refers to angulation (or tip) of the long axis of the *crown*, not to angulation of the long axis of the entire tooth. As orthodontists, we work specifically with the crowns of teeth and, therefore, crowns should be our communication base or referent, just as they are our clinical base. The gingival portion of the long axis of each crown was distal to the incisal portion, varying with the individual tooth type. The long axis of the crown for all teeth, except molars, is judged to be the middevelopmental ridge, which is the most prominent and centermost vertical portion of the labial or buccal surface of the crown. The long axis of the molar crown is identified by the dominant vertical groove on the buccal surface of the crown.

3. *Crown inclination* (labiolingual or buccolingual inclination). *Crown inclination* refers to the labiolingual or buccolingual inclination of the long axis of the *crown*, not to the inclination of the long axis of the entire tooth. (See Fig. 6.) The inclination of all the crowns had a consistent scheme:

A. ANTERIOR TEETH (CENTRAL AND LATERAL INCISORS): Upper and lower anterior crown inclination was sufficient to resist overeruption of anterior teeth and sufficient also to allow proper distal positioning of the contact points of the upper teeth in their relationship to the lower teeth, permitting proper occlusion of the posterior crowns.

B . UPPER POSTERIOR TEETH (CANINES THROUGH MOLARS): A lingual crown inclination existed in the upper posterior crowns. It was constant and similar from the canines through the second premolars and was slightly more pronounced in the molars.

C . LOWER POSTERIOR (CANINES THROUGH MOLARS) . The lingual crown inclination in the lower posterior teeth progressively increased from the canines through the second molars.

4. *Rotations*. There were no rotations.

5. *Spaces*. There were no spaces; contact points were tight.

6. *Occlusal plane*. The plane of occlusion varied from generally flat to a slight curve of Spee.

The six keys to normal occlusion contribute individually and collectively to the total scheme of occlusion and, therefore, are viewed as essential to successful orthodontic treatment.

Key I. Molar relationship. The first of the six keys is molar relationship. The nonorthodontic normal models consistently demonstrated that the distal surface of the distobuccal cusp of the upper first permanent molar occluded with the mesial surface of the mesiobuccal cusp of the lower second molar (Fig. 1). Therefore, one must question the sufficiency of the traditional description of normal molar relationship. As Fig. 2, 1 shows, it is possible for the mesiobuccal cusp of the upper first permanent molar to occlude in the groove between the mesial and middle cusps of the lower first permanent molar (as sought by Angle) while leaving a situation unreceptive to normal occlusion.

The closer the distal surface of the distobuccal cusp of the upper first permanent molar

approaches the mesial surfaces of the mesiobuccal cusp of the lower second molar, the better the opportunity for normal occlusion (Fig. 2,2,3,4). Fig. 1 and 2, 4 exhibit the molar relationship found, without exception, in every one of the 120 nonorthodontic normal models; that is, the distal surface of the upper first permanent molar contacted the mesial surface of the lower second permanent molar.

Key II. Crown angulation (tip). The gingival portion of the long axes of all crowns was more distal than the incisal portion (Fig. 3). In Fig. 4, crown tip is expressed in degrees, plus or minus. The degree of crown tip is the angle between the long axis of the crown (as viewed from the labial or buccal surface) and a line bearing 90 degrees from the occlusal plane. A "plus reading" is awarded when the gingival portion of the long axis of the crown is distal to the incisal portion. A "minus reading" is assigned when the gingival portion of the long axis of the crown is mesial to the incisal portion.

Each nonorthodontic normal model had a distal inclination of the gingival portion of each crown; this was a constant. It varied with each tooth type, but within each type the tip pattern was consistent from individual to individual (quite as the locations of contact points were found by Wheeler, in *An Atlas of Tooth Form*, to be consistent for each tooth type).

Normal occlusion is dependent upon proper distal crown tip, especially of the upper anterior teeth since they have the longest crowns. Let us consider that a rectangle occupies a wider space when tipped than when upright (Fig. 5). Thus, the degree of tip of incisors, for example, determines the amount of mesiodistal space they consume and, therefore, has a considerable effect on posterior occlusion as well as anterior esthetics.

Key III. Crown inclination (labiolingual of buccolingual inclination). The third key to normal occlusion is crown inclination (Fig. 6). In this article, crown inclination is expressed in plus or minus degrees, representing the angle formed by a line which bears 90 degrees to the occlusal plane and a line that is tangent to the bracket site (which is in the middle of the labial or buccal long axis of the clinical crown, as viewed from the mesial or distal). A plus reading is given if the gingival portion of the tangent line (or of the crown) is lingual to the incisal portion, as shown in Fig. 6, A. A minus reading is recorded when the gingival portion of the tangent line (or of the crown) is labial to the incisal portion, as illustrated in Fig. 6, B.

A. ANTERIOR CROWN INCLINATION. Upper and lower anterior crown inclinations are intricately complementary and significantly affect overbite and posterior occlusion. Properly inclined anterior crowns contribute to normal overbite and posterior occlusion, when too straight-up and -down they lose their functional harmony and overeruption results. In Fig. 7, A the upper posterior crowns are forward of their normal position when the upper anterior crowns are insufficiently inclined. When anterior crowns are properly inclined, as on the overlay of Fig. 7, B, one can see how the posterior teeth are encouraged into their normal positions. The contact points move distally in concert with the increase in positive (+) upper anterior crown inclination.

Even when the upper posterior teeth are in proper occlusion with the lower posterior teeth, undesirable spaces will result somewhere between the anterior and posterior teeth, as shown in Fig. 8, if the inclination of the anterior crowns is not sufficient. This space, in treated cases, is often incorrectly blamed on tooth size discrepancy.

B. POSTERIOR CROWN INCLINATION— UPPER. The pattern of upper posterior crown inclination was consistent in the nonorthodontic normal models. A minus crown inclination existed in each crown from the upper canine through the upper second premolar. A slightly more negative crown inclination existed in the upper first and second permanent molars (Fig. 9).

C. POSTERIOR CROWN INCLINATION— LOWER. The lower posterior crown inclination pattern also was consistent among all the nonorthodontic normal models. A progressively greater "minus" crown inclination existed from the lower canines through the lower second molars (Fig. 10).

Tip and torque. Before continuing to the fourth key to normal occlusion, let us more thoroughly discuss a very important factor involving the clinical amplications of the second and third keys to occlusion (angulation and inclination) and how they collectively affect the upper anterior crowns and then the total occlusion.

As the anterior portion of an upper rectangular arch wire is lingually torqued, a proportional amount of mesial tip of the anterior crowns occurs. If you ever felt you were losing ground in tip when increasing anterior torque, you were right.

To better understand the mechanics involved in tip and torque, let us picture an unbent rectangular arch wire with vertical wires soldered at 90 degrees, spaced to represent the upper central and lateral incisors, as in A and B of Fig. 11. As the anterior portion of the arch wire is torqued lingually, the vertical wires begin to converge until they become the spokes of a wheel when the arch wire is torqued 90 degrees as progressively seen in Fig. 11, C, D, and E.

The ratio is approximately 4:1. For every 4 degrees of lingual crown torque, there is 1 degree of mesial convergence of the gingival portion of the central and lateral crowns. For example, as in C, if the arch wire is lingually torqued 20 degrees in the area of the central incisors, then there would be a resultant -5° mesial convergence of each central and lateral incisor. In that the average distal tip of the central incisors is $+5^\circ$, it would then be necessary to place $+10^\circ$ distal tip in the arch wire to accomplish a clinical $+5^\circ$ distal tip of the crown. This mechanical problem can be greatly eased if tip and torque are constructed in the brackets rather than the arch wire.

Key IV. Rotations. The fourth key to normal occlusion is that the teeth should be free of undesirable rotations. An example of the problem is seen in Fig. 12, a superimposed molar outline showing how the molar, if rotated, would occupy more space than normal, creating a situation unreceptive to normal occlusion.

Key V. Tight contacts. The fifth key is that the contact points should be tight (no spaces). Persons who have genuine tooth-size discrepancies pose special problems, but in the absence of such abnormalities tight contact should exist. Without exception, the contact points on the nonorthodontic normals were tight. (Serious tooth-size discrepancies should be corrected with jackets or crowns, so the orthodontist will not have to close spaces at the expense of good occlusion.)

Key VI. Occlusal plane. The planes of occlusion found on the nonorthodontic normal models

ranged from flat to slight curves of Spee. Even though not all of the nonorthodontic normals had flat planes of occlusion, I believe that a flat plane should be a treatment goal as a form of overtreatment. There is a natural tendency for the curve of Spee to deepen with time, for the lower jaw's growth downward and forward sometimes is faster and continues longer than that of the upper jaw, and this causes the lower anterior teeth, which are confined by the upper anterior teeth and lips, to be forced back and up, resulting in crowded lower anterior teeth and/or a deeper overbite and deeper curve of Spee.

At the molar end of the lower dentition, the molars (especially the third molars) are pushing forward, even after growth has stopped, creating essentially the same results. If the lower anterior teeth can be held until after growth has stopped and the third molar threat has been eliminated by eruption or extraction, then all should remain stable below, assuming that treatment has otherwise been proper. Lower anterior teeth need not be retained after maturity and extraction of the third molars, except in cases where it was not possible to honor the masculature during treatment and those cases in which abnormal environmental or hereditary factors exist.

Intercuspatation of teeth is best when the plane of occlusion is relatively flat (Fig. 13, B). There is a tendency for the plane of occlusion to deepen after treatment, for the reasons mentioned. It seems only reasonable to treat the plane of occlusion until it is somewhat flat or reverse to allow for this tendency. In most instances one must band the second permanent molars to get an effective foundation for leveling of the lower and upper planes of occlusion.

A deep curve of Spee results in a more contained area for the upper teeth, making normal occlusion impossible. In Fig. 13, A, only the upper first premolar is properly intercuspally placed. The remaining upper teeth, anterior and posterior to the first premolar, are progressively in error.

A reverse curve of Spee is an extreme form of overtreatment, allowing excessive space for each tooth to be intercuspally placed (Fig. 13, C).

Conclusion and comment

Although normal persons are as one of a kind as snowflakes, they nevertheless have much in common (one head, two arms, two legs, etc.). The 120 nonorthodontic normal models studied in this research differed in some respects, but all shared the six characteristics described in this report. The absence of any one or more of the six results in occlusion that is proportionally less than normal.

It is possible, of course, to visualize and to find models which have deficiencies, such as the need for caps, preventing proper contact, but these are dental problems, not orthodontic ones. Sometimes there are compromises to be weighed, and these pose the true challenge to the professional judgment of the orthodontist. As responsible specialists, we are here to attempt to achieve the maximum possible benefit for our patients. We have no better example for emulation than nature's best, and in the absence of an abnormality outside our control, why should any compromise be accepted?

Successful orthodontic treatment involves many disciplines, not all of which are always within our control. Compromise treatment is acceptable when patient cooperation or genetics demands it. Compromise treatment should not be acceptable when treatment limitations do not exist. In that nature's nonorthodontic normal models provide such a beautiful and consistent guideline, it seems that we should, when possible, let these guidelines be our measure of the static relationship of successful orthodontic treatment. Achieving the final desired occlusion is the purpose of attending to the six keys to normal occlusion.

1. Wheeler, R. C.: An atlas of tooth form, ed. 4, Philadelphia, 1969, W. B. Saunders Company.

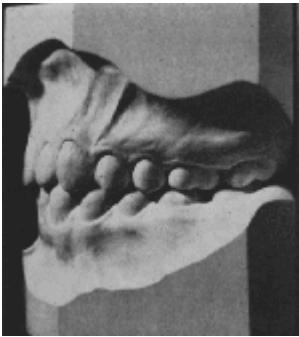

Fig. 1. Improper molar relationship.

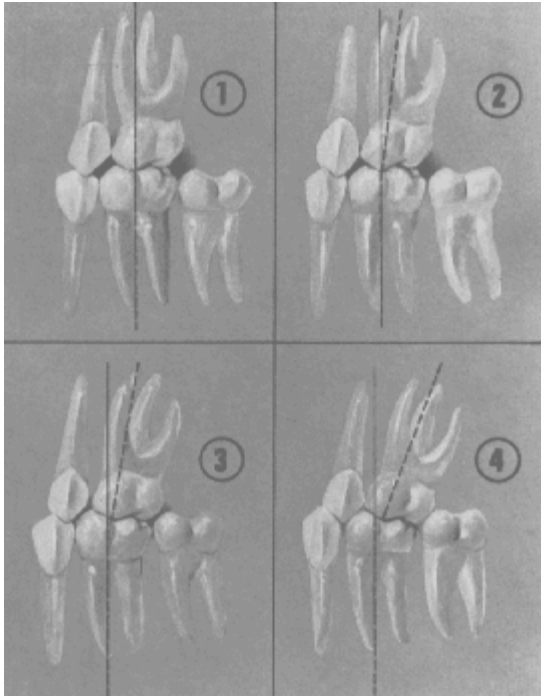


Fig. 2. 1, Improper molar relationship. 2, Improved molar relationship. 3, More improved molar relationship. 4, Proper molar relationship.

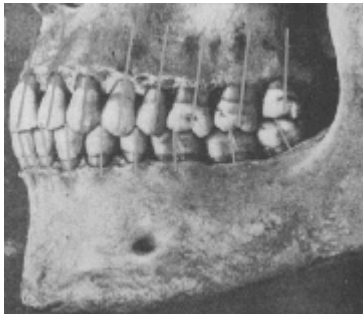


Fig. 3. Normally occluded teeth demonstrate gingival portion of crown more distal than occlusal portion of crown. (After specimen in possession of Dr. F. A. Peeso, from Turner American Textbook of Prosthetic Dentistry, Philadelphia, 1913, Lea & Febiger.)

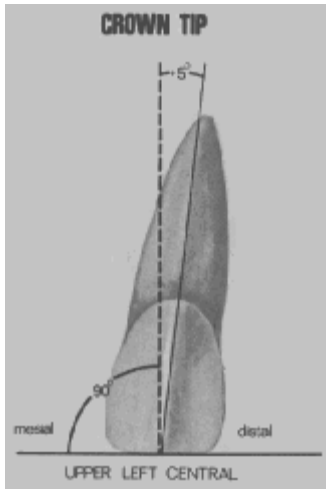


Fig. 4. Crown angulation (tip)— long axis of crown measured from line 90 degrees to occlusal plane.




Fig. 5. A rectangle that is angulated occupies more mesiodistal space than a nonangulated rectangle (that is, upper central and lateral incisors).

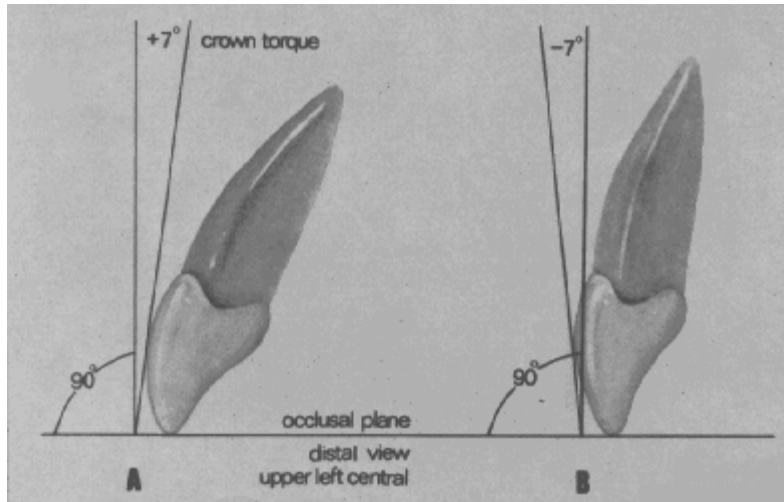


Fig. 6. Crown inclination is determined by the resulting angle between a line 90 degrees to the occlusal plane and a line tangent to the middle of the labial or buccal clinical crown.

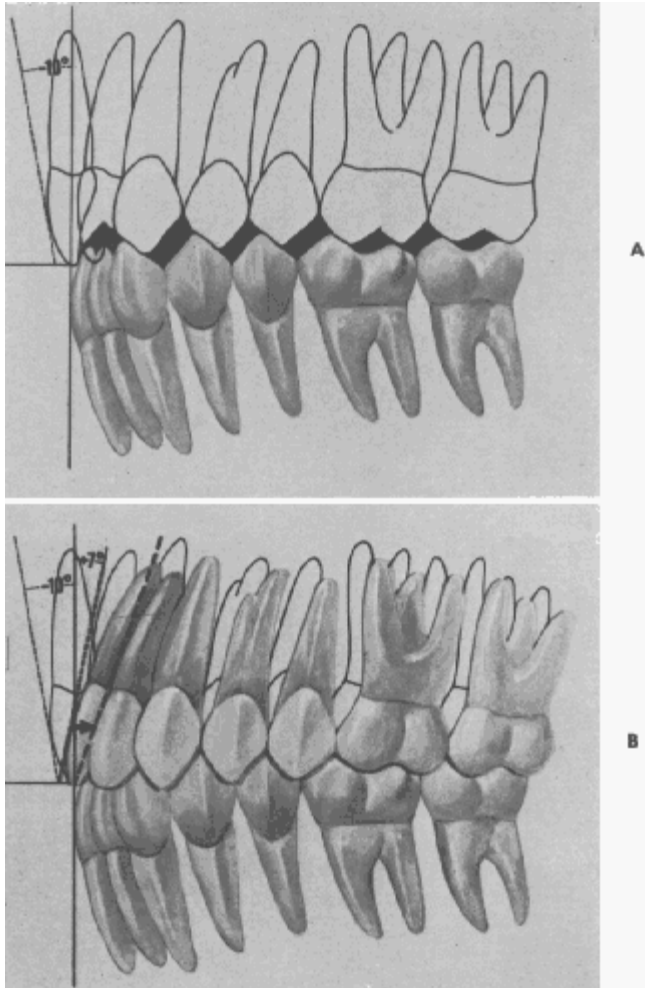


Fig. 7. A, Improperly inclined anterior crowns result in all upper contact points being mesial, leading to improper occlusion. **B,** Demonstration, on an overlay, that when the anterior crowns are properly inclined the contact points move distally, allowing for normal occlusion.

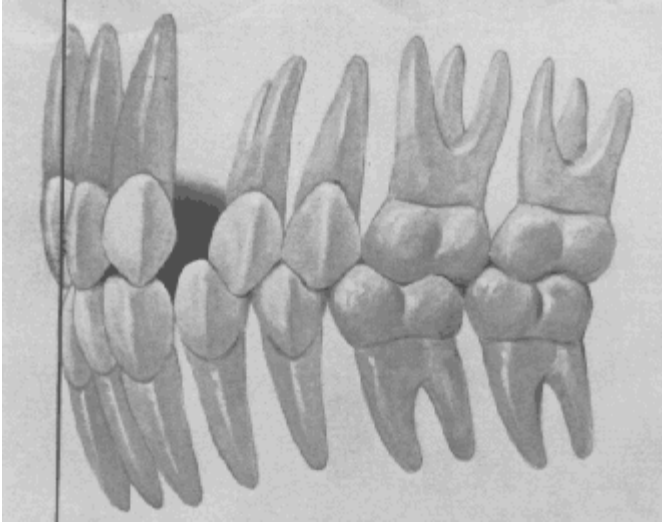


Fig. 8. Spaces resulting from normally occluded posterior teeth and insufficiently inclined anterior teeth are often falsely blamed on tooth size discrepancy.

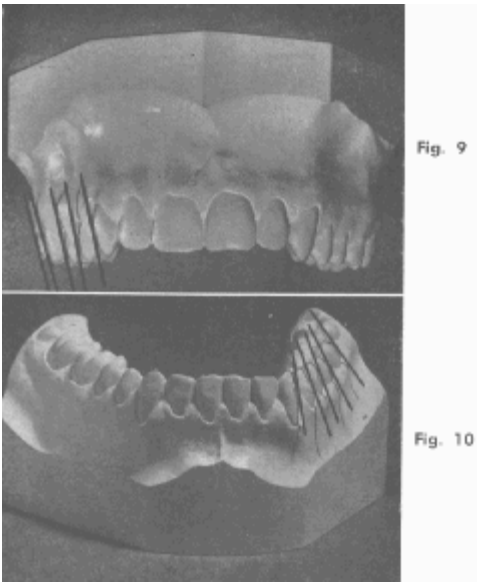


Fig. 9. A lingual crown inclination generally occurs in normally occluded upper posterior crowns. The inclination is constant and similar from the canines through the second premolars and slightly more pronounced in the molars.
Fig. 10. The lingual crown inclination of normally occluded lower posterior teeth progressively increases from the canines through the second molars.

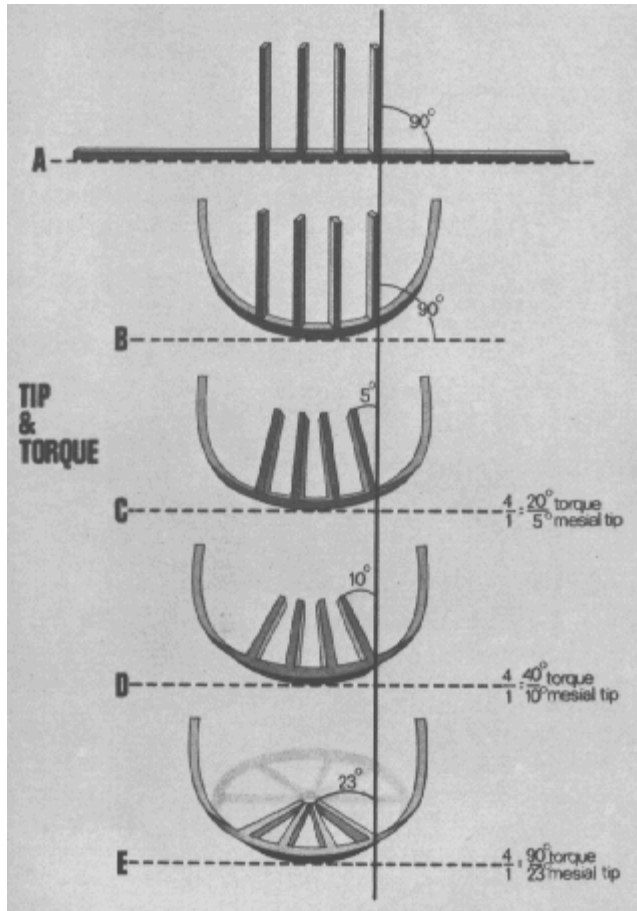


Fig. 11. The wagon wheel. Anterior arch wire torque negates arch wire tip in a ratio of four to one.

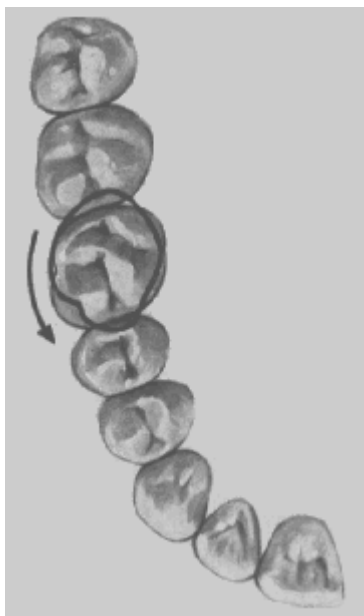

Fig. 12. A rotated molar occupies more mesiodistal space, creating a situation unreceptive to normal occlusion.

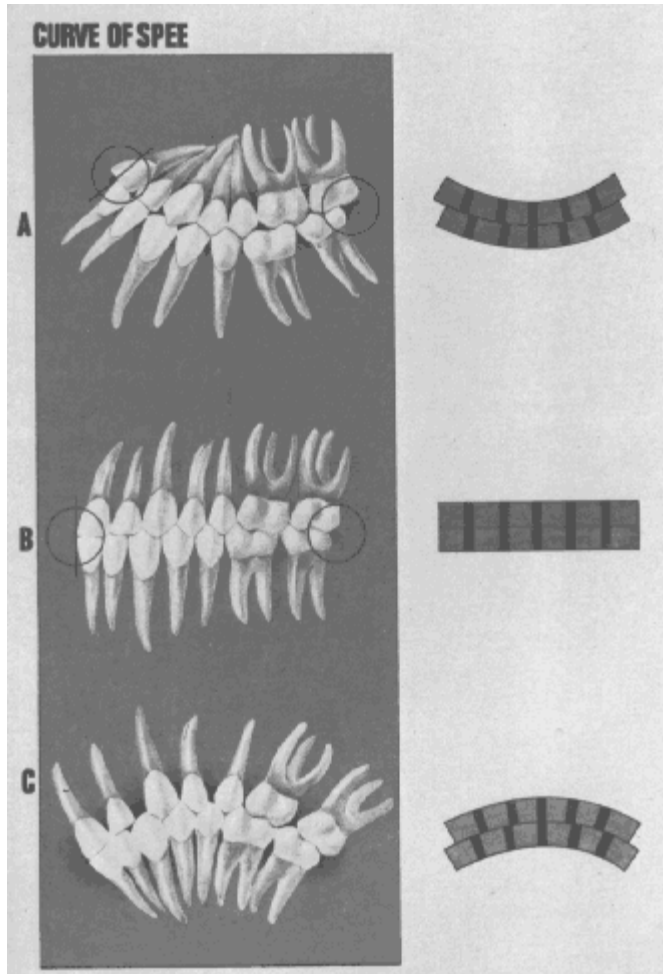


Fig. 13. A, A deep curve of Spee results in a more confined area for the upper teeth, creating spillage of the upper teeth progressively mesially and distally. **B**, A flat plane of occlusion is most receptive to normal occlusion. **C**, A reverse curve of Spee results in excessive room for the upper teeth.

This document was created with Win2PDF available at <http://www.daneprairie.com>.
The unregistered version of Win2PDF is for evaluation or non-commercial use only.