

---

# Transverse Dimension and Long-Term Stability

Robert L. Vanarsdall, Jr

**This article emphasizes the critical importance of the skeletal differential between the width of the maxilla and the width of the mandible. Undiagnosed transverse discrepancy leads to adverse periodontal response, unstable dental camouflage, and less than optimal dentofacial esthetics. Hundreds of adult retreatment patients corrected for significant maxillary transverse deficiency using surgically assisted maxillary expansion (similar to osseous distraction) has produced excellent stability. Eliciting tooth movement for children (orthopedics, lip bumper, Cetlin plate) in all three planes of space by muscles, eruption, and growth, develops the broader arch form (without the mechanical forces of fixed or removable appliances) and has also demonstrated impressive long term stability. (Semin Orthod 1999;5: 171-180.) Copyright © 1999 by W.B. Saunders Company**

The decade of the 1990s should have been declared the decade of the transverse dimension in orthodontics. One of the ultimate goals of orthodontics is long-term stability. Research has established that stability starts with proper diagnosis. A key to correct diagnosis is evaluation in three planes of space. During this decade, it has been shown that clinical inspection for transverse maxillary deficiency is inadequate for diagnostic value.<sup>1,2</sup> Use of the study casts, the icon of the past, are not the basis for the skeletal diagnosis in the transverse dimension. The posterior buccolingual dental landmarks are also not the determining factor. The presence or absence of clinical posterior dental crossbite does not indicate the absence of a transverse skeletal discrepancy. Ricketts<sup>3</sup> has emphasized the use of the frontal analysis to determine the comparisons between the width of the dental arches, the alveolar arches and the skeletal bases. Treatment planning for the transverse skeletal problem requires a determination of the severity of the

discrepancy and the differentiation between the skeletal and dental components. Ruest and Doyle have shown that Class II malocclusions are smaller in width measurement than normal, and there is a 3-mm difference between the maxillary skeletal width of Class I (normal) and Class II Division 1 males at age 18.<sup>4,5</sup> Unfortunately, the posteroanterior (PA) cephalometric radiograph that provides this critical information is not used by most clinicians to assess the transverse dimension but usually only to evaluate asymmetry.

The PA cephalogram is the most readily available and reliable film to identify and evaluate transverse skeletal dysplasia. Ricketts<sup>6</sup> developed the Rocky Mountain analysis and has suggested norms and differentials that allow one to determine departure from the ideal and to establish the degree of treatment difficulty for a particular patient's problem. The maxillomandibular transverse differential index is the expected maxillomandibular difference (an established norm for different ages) minus the actual recorded maxillomandibular difference. The expected maxillomandibular difference is defined as the age-appropriate-expected AG to GA distance (right and left antegonial notches-mandibular width) minus the age-appropriate-expected J point to J point (or Mx) distance (left and right intersections of the maxillary tuberosity and the zygomatic buttress-maxillary width). The actual max-

---

*From the Department of Orthodontics, University of Pennsylvania, School of Dental Medicine, Philadelphia, PA.*

*Address correspondence to Robert L. Vanarsdall, Jr, DDS, Professor and Chairman, Department of Orthodontics, University of Pennsylvania, School of Dental Medicine, 4001 Spruce St, Philadelphia, PA 19104-6003.*

*Copyright © 1999 by W.B. Saunders Company  
1073-8746/99/0503-0006\$10.00/0*

illomandibular difference is defined as the actual AG to GA measurement minus the actual J point to J point measurement (Fig 1).

The normal (maxillary and mandibular) values provided here are for the Caucasian race (values for all racial and ethnic groups and even genders will vary), but the differential between

the width of the maxilla and width of the mandible is the critical evaluation for the individual patient. After a diagnosis of transverse jaw discrepancy has been established, using arch widths, arch form, and radiographic techniques, treatment options and the appropriate treatment approach can be determined. It does not

**Maxillomandibular Transverse Differential Index**

	<u>9 Year Old</u>	<u>Change/Yr to age 16</u>	<u>Normal (Expected)</u>	<u>Patient (Actual)</u>
Effective Mandibular Width	(GA to AG) 76 ±3 mm	+1.4 mm	_____	_____
Effective Maxillary Width	(JR to JL) 62 ± 3 mm	+0.6 mm	_____	_____

**Normal Values**

Age	Maxillary	Mandibular	Difference
9	62.0	76.0	14.0
10	62.6	77.4	14.8
11	63.2	78.8	15.6
12	63.8	80.2	16.4
13	64.4	81.6	17.2
14	65.0	83.0	18.0
15	65.6	84.4	18.8
16 (Adult)	66.2	85.8	19.6

Expected Maxillomandibular Diff. = Expected Mand. Width - Expected Max. Width \_\_\_\_\_ mm

Actual Maxillomandibular Differential = Actual Mand. Width - Actual Max. Width \_\_\_\_\_ mm

Expected-Actual Maxillomandibular Differential \_\_\_\_\_ mm

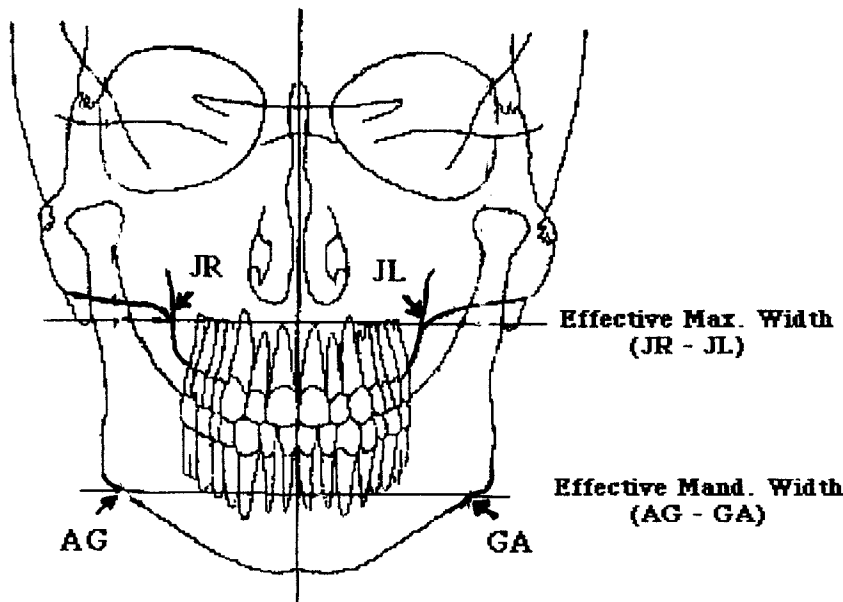
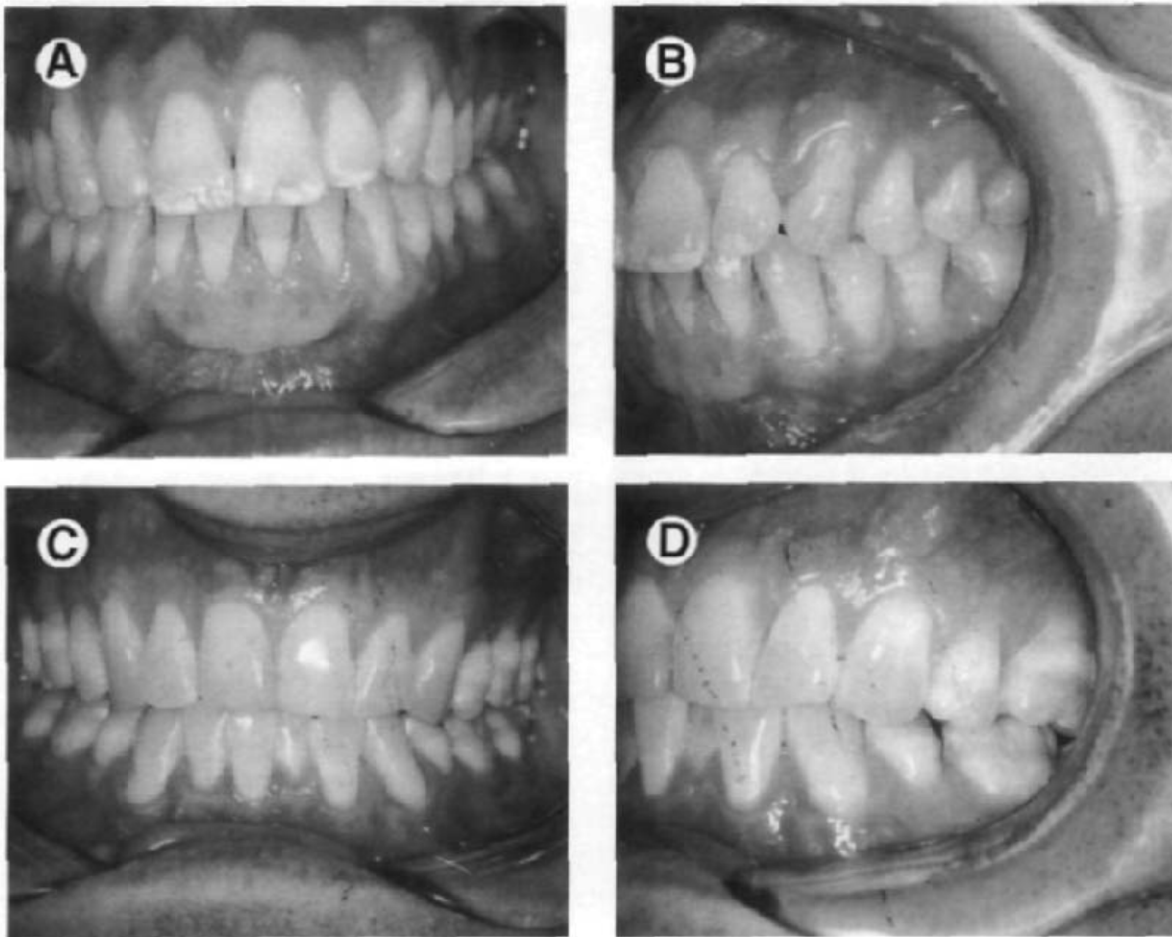


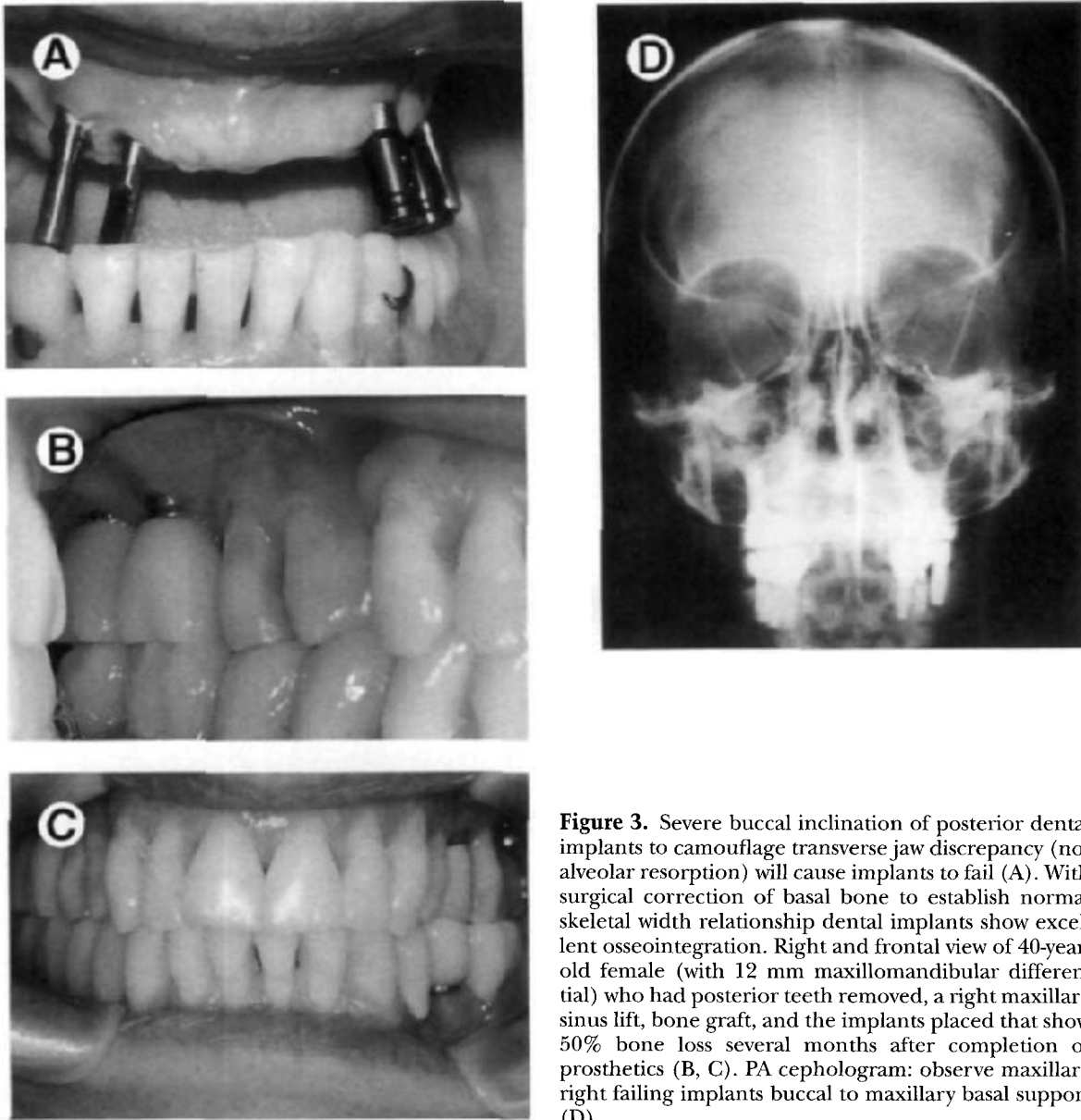
Figure 1. Landmarks used to measure effective mandibular and maxillary width. Worksheet used to determine the radiographic magnitude of the maxillomandibular transverse differential index and location of the discrepancy (maxilla, mandible or both).

matter whether teeth are extracted or not, if the transverse discrepancy is undiagnosed, the adverse periodontal effects of gingival recession will be experienced by the patient (Fig 2A-D). Even with the placement of implants the implant fixtures will fail when there is a significant transverse skeletal problem (Fig 3A-D). Currently most treatment procedures (fixed appliances and functional therapy) are used to affect the transverse plane where treatment potentials are much more limited than other planes. Orthodontics used to achieve unstable dental camouflage of the underlying skeletal discrepancy in the transverse plane has been shown to lead to unrewarding treatment results<sup>7,8</sup> (Fig 4A-C). Orthopedic maxillary expansion results in more widening at the canines than at the molars (with a 3:2 ratio) and is the result of skeletal (sutural

openings), dental (tipping), and alveolar (bending and remodelling) changes. As a child matures, more force is required and less skeletal expansion and more dental tipping occurs.<sup>9</sup> Krebs<sup>9</sup> showed this in a study using metal markers during orthopedic expansion in children and adolescents. Children showed 50% skeletal and 50% dental expansion, whereas the adolescent showed 35% skeletal and 65% dental expansion. After orthodontic appliance removal, the dental tipping and alveolar bending components of transverse expansion tend to relapse.<sup>9</sup> Therefore, when orthopedic maxillary expansion is used to correct transverse maxillary deficiency, overcorrection by as much as 50% has been recommended. Overcorrection, however, is not recommended for surgically assisted expansion. In a study of Kuo and Will,<sup>10</sup> 9 of 21 patients who



**Figure 2.** Frontal and lateral views of a male nonextraction patient 15 years posttreatment. The 10 mm maxillomandibular differential was camouflaged and undiagnosed (A, B). Similar male treated extraction with 10 mm maxillomandibular differential. Observe root exposure in posterior segments for both patients (C, D).

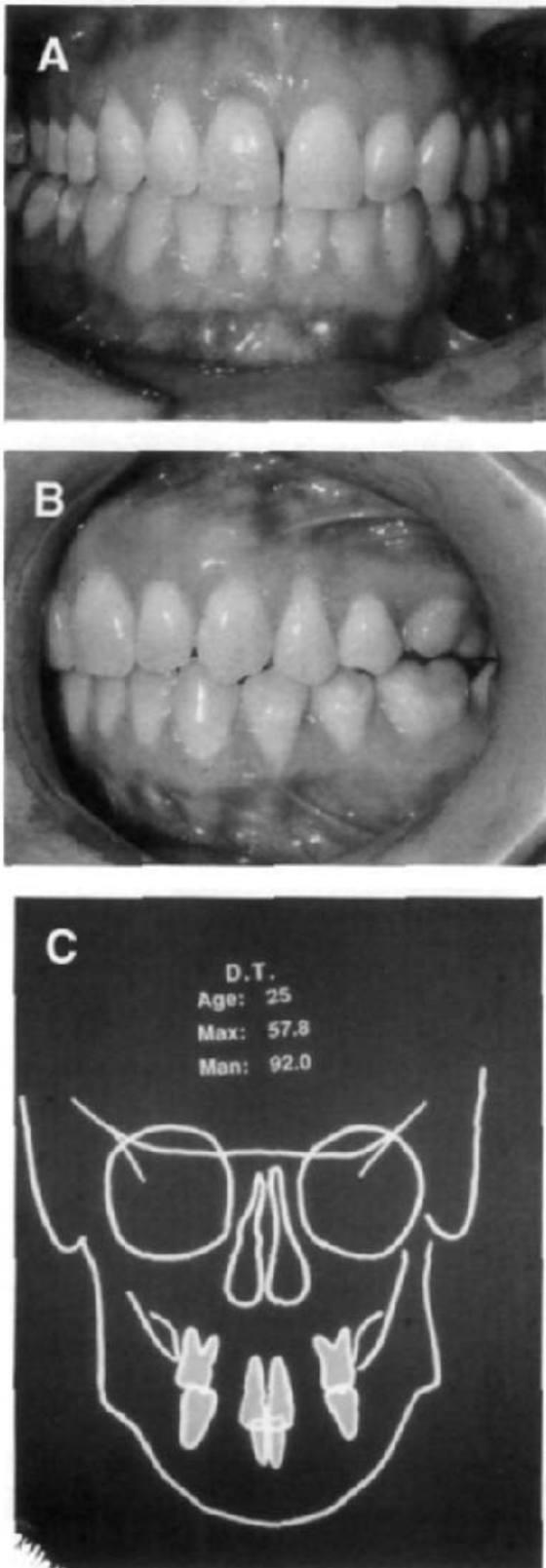


**Figure 3.** Severe buccal inclination of posterior dental implants to camouflage transverse jaw discrepancy (not alveolar resorption) will cause implants to fail (A). With surgical correction of basal bone to establish normal skeletal width relationship dental implants show excellent osseointegration. Right and frontal view of 40-year-old female (with 12 mm maxillomandibular differential) who had posterior teeth removed, a right maxillary sinus lift, bone graft, and the implants placed that show 50% bone loss several months after completion of prosthetics (B, C). PA cephalogram: observe maxillary right failing implants buccal to maxillary basal support (D).

underwent surgically assisted maxillary expansion showed the same amount of basal maxillary expansion as molar expansion with a mean of 84% skeletal movement.

After sutural closure or significant slowing in maxillary transverse growth (15 years for females and 16 years of age for males) expansion is largely unsuccessful, because the expansion is primarily alveolar or dental tipping with little or no basal skeletal movement. The mature adolescent or adult patient may be unable to activate the expansion appliance and may experience severe pain, pressure necrosis of soft tissue,

tipping and extrusion of maxillary teeth, bending of alveolar bone, uncontrolled relapse (Fig 5A-C), and periodontal complications.<sup>11</sup> In addition, the patients are predisposed to gingival recession and dental instability that is seen usually years after orthodontic treatment has been completed. However, for the mature patient, if the clinical and radiographic analysis shows less significant transverse maxillary deficiency (less than 5 mm total maxillomandibular discrepancy) sufficient buccal maxillary bone may remain to allow dental tipping and camouflage of the transverse skeletal pattern. A study at the



University of Pennsylvania determined that buccal gingival recession for untreated patients (with transverse discrepancy 5 mm greater than the normal 19.6 mm maxillomandibular differential) is directly correlated with maxillary transverse deficiency<sup>12</sup> (Fig 6).

Numerous orthodontic patients have been retreated using the surgically assisted maxillary expansion technique with extremely stable results. DePaoli et al<sup>13</sup> evaluated 10 patients 6 months to 5 years after treatment and their, and other reports have indicated good stability.<sup>14,15</sup> Surgical-only (segmental maxillary osteotomy) expansion has been reported to be the least stable orthognathic procedure.<sup>16</sup>

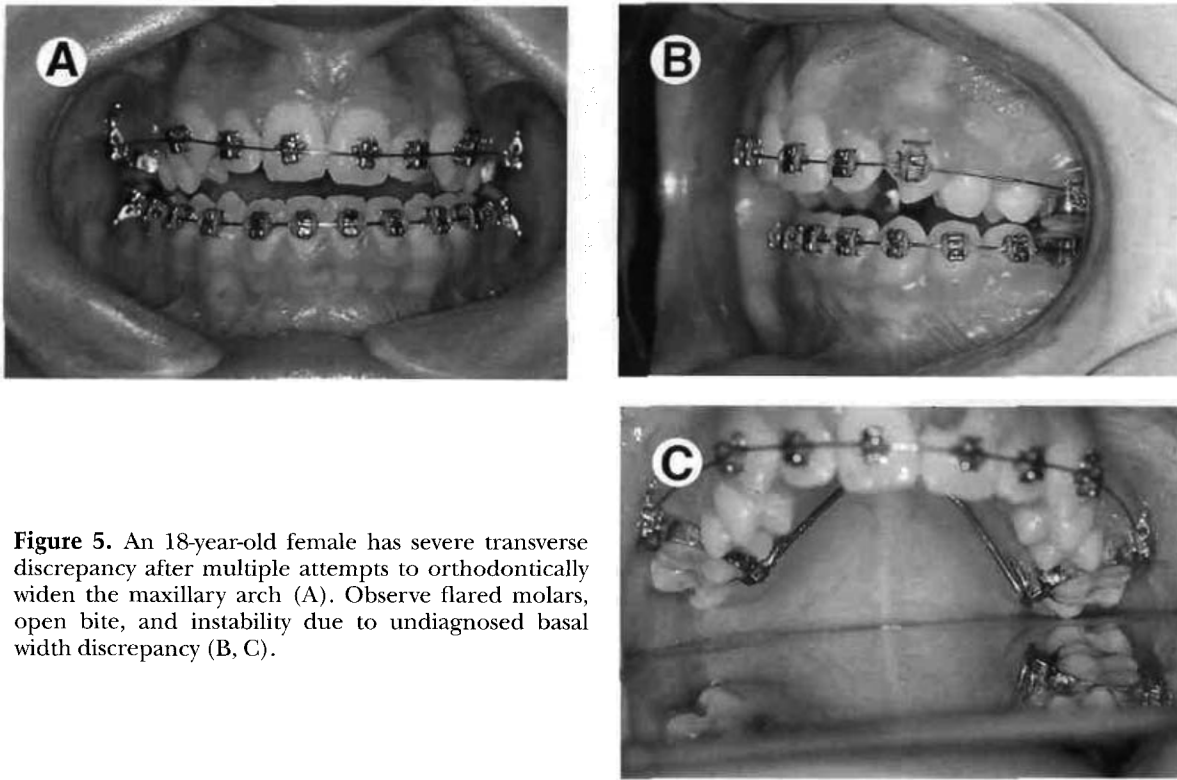
Orthodontic-orthopedic expansion can be attempted in patients who require only maxillary transverse expansion where the differential is less than 5 mm, transverse growth potential exists, normal gingival tissues are present in the posterior areas, and the patient does not have a narrow maxilla with an extremely wide mandible. The indications for surgically assisted rapid palatal expansion have been reported by Betts et al.<sup>17</sup>

It is generally accepted by orthodontists that mechanically pushing or pulling the teeth to expand the dental arches has not been stable. However, with a changed environment resulting from functional appliances and growth, stability has been observed.

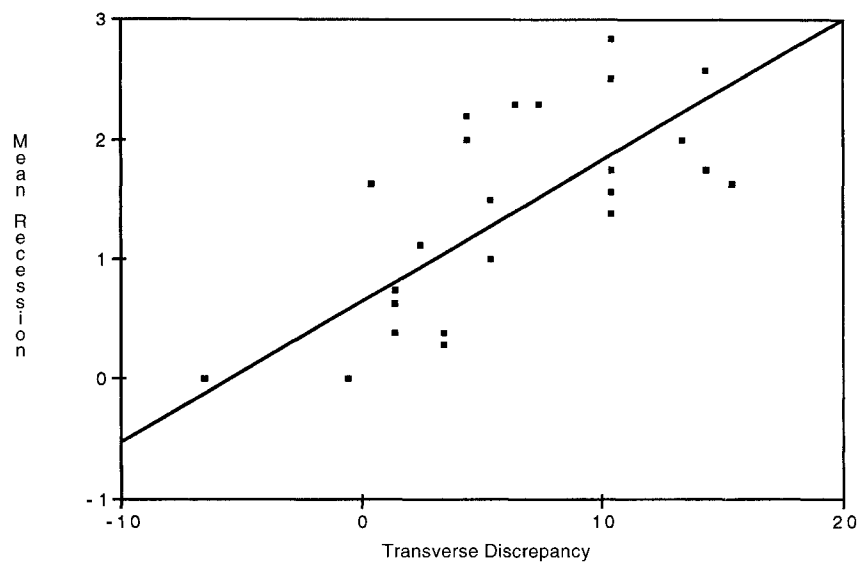
### Arch Form and Stability

Stability of arch form has been considered to be one of the most elusive goals of treatment. Diagnosis and treatment of the transverse dimension may provide some insight into solving this problem. Normal values measured in the molar areas for comparing skeletal bases do not reflect dysplastic arch form in the anterior portion of the arch. For the growing child, orthopedics and Cetlin mechanics<sup>18</sup> can provide a stable correction. In the adult patient, correction of the basal

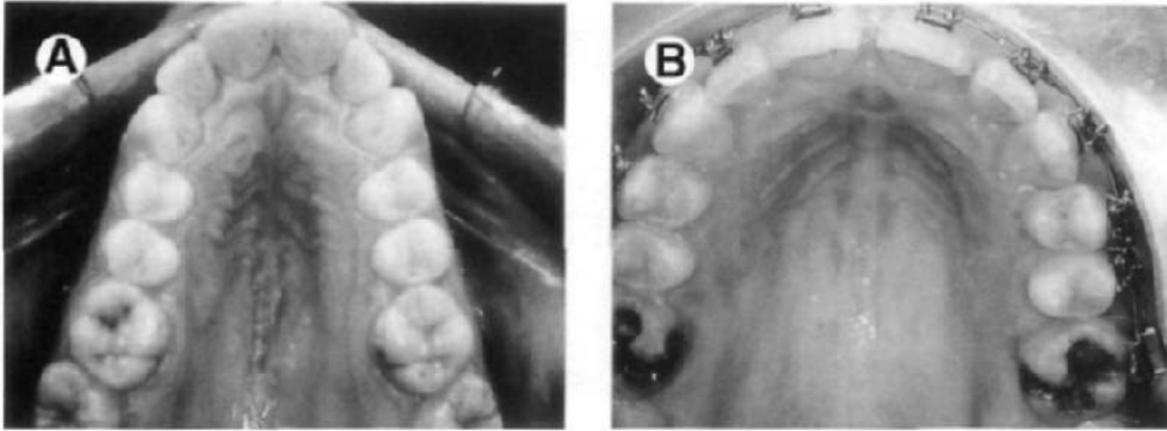
←  
**Figure 4.** Frontal and lateral views of 25-year-old patient with 15 mm maxillomandibular difference in which the transverse skeletal discrepancy was camouflaged (A,B). Observe gingival recession and root exposure. Case is very unstable, has mobile teeth, and poor dental esthetics due to negative space between cheeks and buccal segments (C).



**Figure 5.** An 18-year-old female has severe transverse discrepancy after multiple attempts to orthodontically widen the maxillary arch (A). Observe flared molars, open bite, and instability due to undiagnosed basal width discrepancy (B, C).



**Figure 6.** Patients were divided into two groups based on the maxillomandibular differential. Patients with  $<5$  mm greater than the normal (19.6) differential were classified as the normal transverse group ( $N = 13$ ) and those with  $>5$  mm above the normal value were classified as the transverse deficient group ( $n = 13$ ). Findings indicated a statistically significant difference between the two groups and mean recession was higher for patients with transverse discrepancy. The coefficient of correlation between transverse skeletal dimension and mean recession was  $r = 0.74$  and was statistically significant ( $P \leq 0.001$ ).

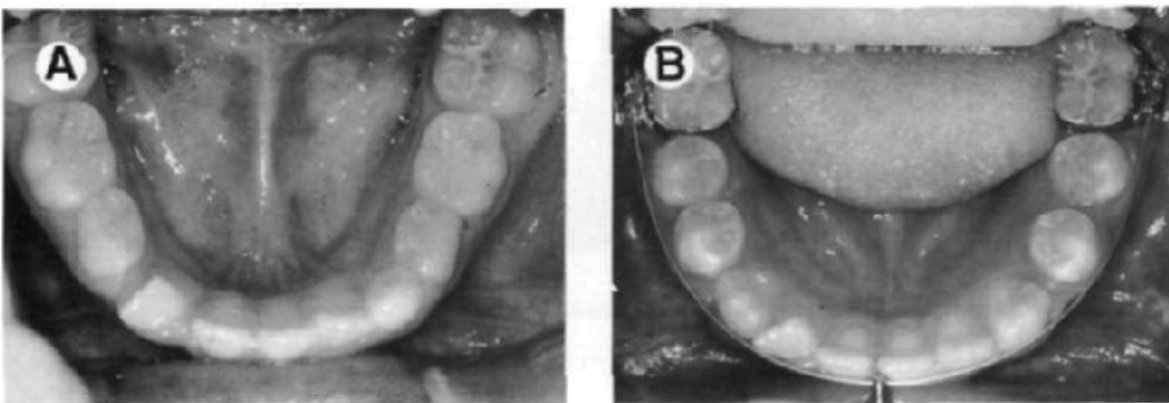


**Figure 7.** Preoperative maxillary occlusal view (A). Note arch form that can be created in three to four months following surgically assisted RPE (B).

arch configuration is accomplished with the aid of a surgical adjunct (eg, surgically assisted rapid palatal expansion.) With surgical-orthodontic correction of maxillary transverse deficiency (basal support), each patient will exhibit the natural broad arch form within several months after bracket and arch wire placement (Fig 7A and B). This does not mean that all mature patients with severe transverse deformity require surgery, but if orthodontics alone is the choice of treatment, the patient, in the interests of stability and periodontal health, would best be treated by establishing posterior dental crossbites distal to the canines.

In a young child, when eliciting tooth movement (orthopedics, lip bumper, Cetlin plate) in all three planes of space by muscles, eruption,

and growth, the dentoalveolar widening that occurs provides the broad arch form in all cases, regardless of facial type. The arch form is not determined mechanically by the arch wire and bracket system. The wider natural or broader arch form is established before attachments are placed on the teeth, with the exception of the first molars. In 50 consecutively treated patients, the lip bumper in the mandibular arch allowed for an average increase of 2.5 mm in width at the cuspids, 4 mm at the first bicuspid, 4.4 mm at the second bicuspid, and 5.5 mm at the first molars.<sup>18</sup> Dental development is enhanced, and with the use of the Cetlin plate (to disengage the occlusion), a spontaneous leveling of the curve of spee, favorable mandibular growth,<sup>19</sup> and early eruption of teeth, including second molars,

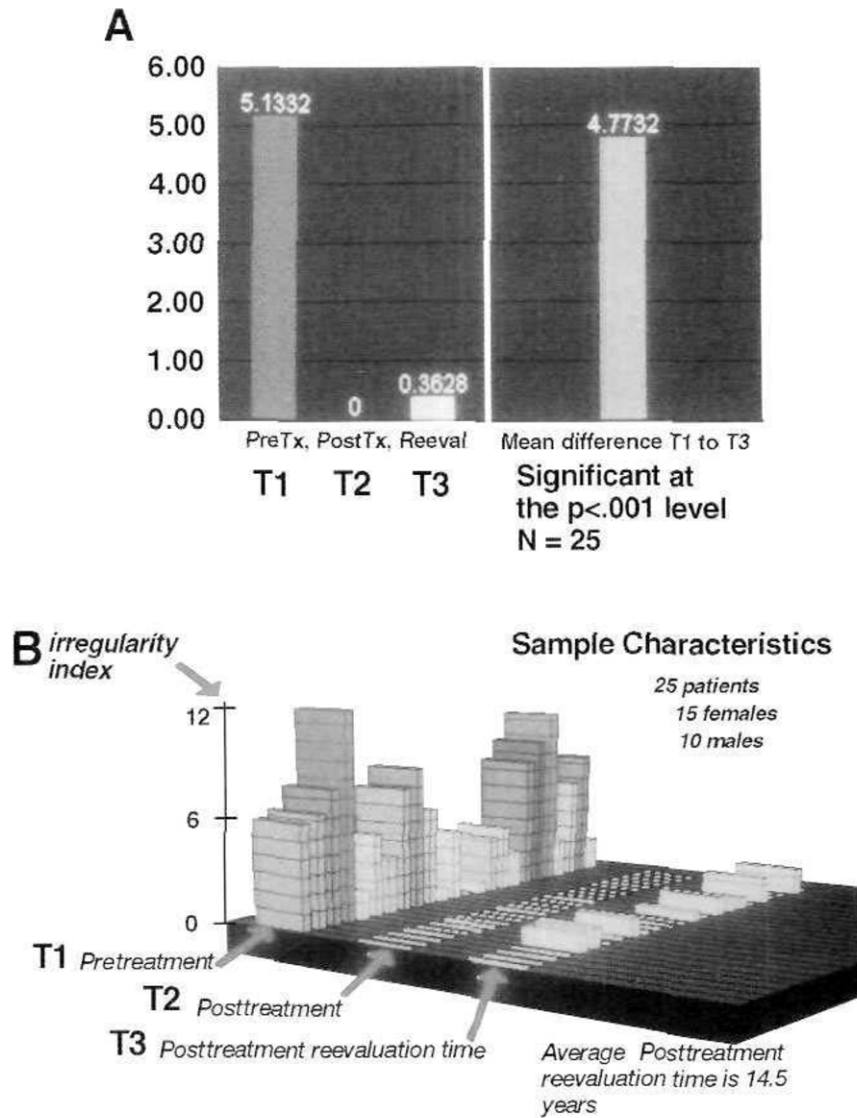


**Figure 8.** Pretreatment occlusal view of blocked out right canine (A). Following lip bumper wear, note arch form that develops before brackets are placed in the natural or broader arch (B). Arch wire is being held in place with a hemostat.

occurs. With headgear, the maxillary dental units widen before attachments are placed as has been described.<sup>18</sup>

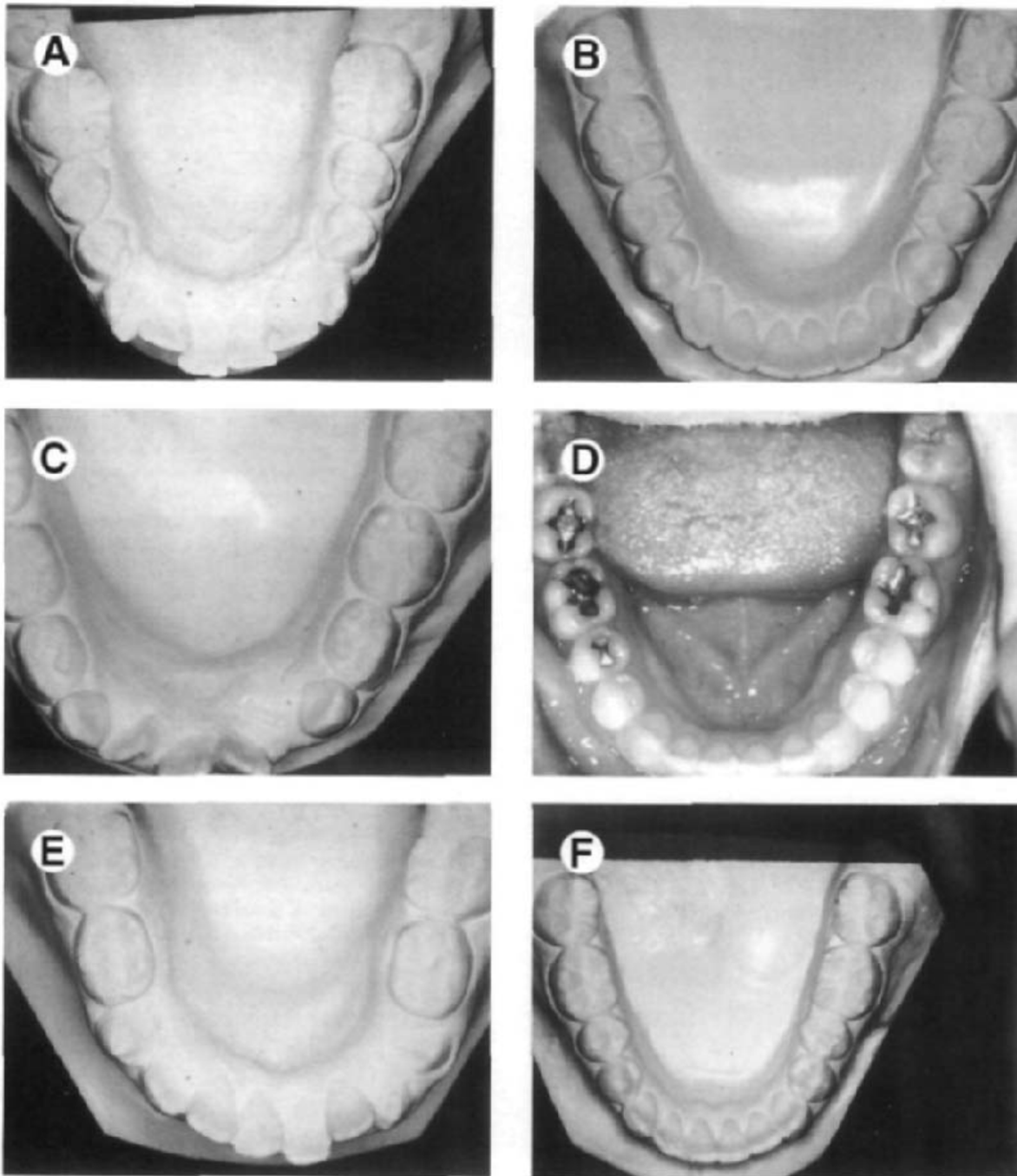
The effort is not to maintain the arch form of the original malocclusion, because this is a major component of the original malocclusion. Through the interaction of the tongue and lip bumper, spontaneous decrowding of lower incisors occurs as space is gained by growth and widening. (Fig 8A and B) The lip bumper allows for dentoalveolar widening and reshaping which is induced without direct attachments to the

teeth except contact at the molar tubes. Because lower incisor crowding is etiologically a multifactorial problem, the author recommends that lower bonded retainers are kept in place for an indefinite time. However, DePaoli<sup>20</sup> evaluated Cetlin cases and found excellent long-term stability (Fig 9A and B), even though lower intercanine width was developed in every case (Fig 10A-F). Fixed retainers were not used to retain lower arch corrections, while lower incisor stripping was used infrequently. Treatment strategies that are not designed to influence growth and



**Figure 9.** Mean irregularity index at T1, T2 and T3. Little's irregularity index was used to evaluate pretreatment study cases of 25 patients (T1), all cases were ideally aligned (T2) and 14.5 years posttreatment the mean irregularity index did not return to 1 (A). Little has stated that 3.5 mm is the maximum irregularity associated with minimum incisor crowding. Bar graph shows individual cases (B).





**Figure 10.** Before treatment (A); 30 years after treatment (B); Before treatment (C); 23 years after treatment (D); Before treatment (E); 25 years after treatment (F). (Courtesy of Dr Norman Cetlin, Newton Center, MA.)

apical base relationships (in three planes of space), or use surgical options, are limited to maintaining arch form of the original malocclusion and may expect satisfactory mandibular alignment in fewer than 30% of long-term cases.<sup>21</sup>

Research continues to confirm stability of treatment strategies based on the most complete diagnostic data base in three planes of space. Hopefully, as the 21st century begins, clinical evidence and proven stability of long-term cases will stimulate interest and encourage clinicians to incorporate transverse skeletal evaluation during routine orthodontic diagnosis.

## References

1. Crosby DR, Jacobs JD, Bell WH. Special adjunctive considerations 1. Transverse (horizontal) maxillary deficiency, in Bell WH (ed): *Modern Practice in Orthognathic and Reconstructive Surgery*, vol 3. Philadelphia, PA, Saunders, 1992, pp 2403-2430.
2. Flickinger CA, Betts NJ, Vanarsdall R, Beideman R: The Use of Transverse Tomography to evaluate the Orthodontic and Orthopedic Effects of Rapid Maxillary Expansion, University of Pennsylvania, Department of Orthodontics, Unpublished Thesis, May 1995.
3. Ricketts RM. The Wisdom of the Bioprogressive Philosophy. *Sem Orthod* 1998;4:201-207.
4. Ruest A. Transverse dimensional growth and developmental crowding in untreated normal occlusions, University of Pennsylvania, Department of Orthodontics, Unpublished Thesis, May 1994.
5. Doyle SK. Transverse dimensional growth and lower incisor crowding in untreated class II division I malocclusions. University of Pennsylvania, Department of Orthodontics, Unpublished Thesis, May 1995.
6. Ricketts RM. Perspectives in the clinical application of cephalometrics, the first fifty years. *Angle Orthod* 1981; 51:115-150.
7. Graber TM, Vanarsdall RL (eds): *Orthodontics: Current Principles and Techniques*, ed 2. St Louis, MO, Mosby, 1994:720.
8. Vanarsdall R, White R. Three-dimensional analysis for skeletal problems. *Int J Adult Orthod Orthognath Surg* 1994;9:159.
9. Krebs A. Mid-palatal expansion studied by the implant method over a seven year period. *Trans Eur Orthod Soc* 1964;131-142.
10. Kuo PC, Will LA. Surgical-Orthodontic Treatment of Maxillary Constriction, *O. Maxillofacial Surg Clin North Am* 1990;2:4.
11. Graber TM, Vanarsdall RL (eds). *Orthodontics: Current Principles and Techniques*, ed 2. St. Louis, MO, Mosby, 1994;715-721.
12. Saacks E, Vanarsdall RL. Evaluation of the Skeletal Transverse Dimension as a Risk Indicator for Maxillary Buccal Gingival Recession in Adults, Unpublished Thesis. University of Pennsylvania, 1994.
13. DePaoli C, Vanarsdall R, Betts N. Dental Stability of Surgically Assisted Rapid Palatal Expansion, Unpublished Thesis, University of Pennsylvania, SDM, 1993.
14. Bays RA, Greco JM. Surgical assisted rapid palatal expansion: An outpatient technique with long-term stability. *J Oral Maxillofac Surg* 1992;50:110-113.
15. Pogrel MA, Raban LB, Vargervik K, Baumrind S. Surgically assisted rapid maxillary expansion in adults. *Int J Adult Orthod Orthognath Surg* 1992;7:37-41.
16. Proffit WR, Turvey TA, Phillips C. Orthognathic Surgery: A hierarchy of stability. *Int J Adult Orthod Orthognathic Surg* 1996;11:191-204.
17. Betts NJ, Vanarsdall RL, Barber HD, Higgins-Barber K, Fonseca RJ. Diagnosis and treatment of transverse maxillary deficiency. *Int J Adult Orthod Orthognathic Surg* 1995;10:75-96.
18. Cetlin NM, TenHoeve A. Nonextraction Treatment. *J Clinical Orthodont* 1983;17:404-413.
19. Johnston LE, Jr. Growth and the class II Patient: Rendering Unto Caesar. *Sem in Orthod* 1998;4:59-62.
20. DePaoli C. Stability of Cetlin Nonextraction Treatment, Unpublished Thesis, Department of Orthodontics, University of Pennsylvania, 1992.
21. Little RM, Wallen TR, Riedel RA. Stability and relapse of mandibular anterior alignment: first premolar extraction cases tested by traditional edgewise orthodontics. *Am J Orthod* 1981;80:349.